

Plasticity of ocular dominance columns in monkey striate cortex

BY D. H. HUBEL, T. N. WIESEL AND S. LEVAY

*Department of Neurobiology, Harvard Medical School,
25 Shattuck Street, Boston, Massachusetts 02115, U.S.A.*

[Plates 1–12]

Ocular dominance columns were examined by a variety of techniques in juvenile macaque monkeys in which one eye had been removed or sutured closed soon after birth. In two monkeys the removal was done at 2 weeks and the cortex studied at $1\frac{1}{2}$ years. Physiological recordings showed continuous responses as an electrode advanced along layer IVC in a direction parallel to the surface. Examination of the cortex with the Fink–Heimer modification of the Nauta method after lesions confined to single lateral-geniculate layers showed a marked increase, in layer IVC, in the widths of columns belonging to the surviving eye, and a corresponding shrinkage of those belonging to the removed eye.

Monocular lid closures were made in one monkey at 2 weeks of age, for a period of 18 months, in another at 3 weeks for 7 months, and in a third at 2 days for 7 weeks. Recordings from the lateral geniculate body showed brisk activity from the deprived layers and the usual abrupt eye transitions at the boundaries between layers. Cell shrinkage in the deprived layers was moderate – far less severe than that following eye removal, more marked ipsilaterally than contralaterally, and more marked the earlier the onset of the deprivation. In autoradiographs following eye injection with a mixture of tritiated proline and tritiated fucose the labelling of terminals was confined to geniculate layers corresponding to the injected eye. Animals in which the open eye was injected showed no hint of invasion of terminals into the deprived layers. Similarly in the tectum there was no indication of any change in the distribution of terminals from the two eyes.

The autoradiographs of the lateral geniculates provide evidence for several previously undescribed zones of optic nerve terminals, in addition to the six classical subdivisions.

In the cortex four independent methods, physiological recording, transneuronal autoradiography, Nauta degeneration, and a reduced-silver stain for normal fibres, all agreed in showing a marked shrinkage of deprived-eye columns and expansion of those of the normal eye, with preservation of the normal repeat distance (left-eye column plus right-eye column). There was a suggestion that changes in the columns were more severe when closure was done at 2 weeks as opposed to 3, and more severe on the side ipsilateral to the closure. The temporal crescent representation in layer IVC of the hemisphere opposite the closure showed no obvious adverse effects. Cell size and packing density in the shrunken IVth layer columns seemed normal.

In one normal monkey in which an eye was injected the day after birth, autoradiographs of the cortex at 1 week indicated only a very mild degree of segregation of input from the two eyes; this had the form of parallel bands. Tangential recordings in layer IVC at 8 days likewise showed considerable overlap of inputs, though some segregation was clearly present; at 30 days the segregation was much more advanced. These preliminary experiments thus suggest that the layer IVC columns are not fully developed until some weeks after birth.

Two alternate possibilities are considered to account for the changes in the ocular dominance columns in layer IVC following deprivation. If one ignores the above evidence in the newborn and assumes that the columns are fully formed at birth, then after eye closure the afferents from the normal eye must extend their territory, invading the deprived-eye columns perhaps by a process of sprouting of terminals. On

the other hand, if at birth the fibres from each eye indeed occupy all of layer IV C, retracting to form the columns only during the first 6 weeks or so, perhaps by a process of competition, then closure of one eye may result in a competitive disadvantage of the terminals from that eye, so that they retract more than they would normally. This second possibility has the advantage that it explains the critical period for deprivation effects in the layer IV columns, this being the time after birth during which retraction is completed. It would also explain the greater severity of the changes in the earlier closures, and would provide an interpretation of both cortical and geniculate effects in terms of competition of terminals in layer IV C for territory on postsynaptic cells.

INTRODUCTION

Physiological experiments in cats and monkeys visually deprived from a young age indicate a certain amount of plasticity in central-nervous pathways, especially at the cortical level. The nature of this plasticity is unclear. Connections present at birth can certainly be made non-functional as a result of deprivation, but whether there are actual morphological changes is not known. Neither is it known whether deprivation can lead to abnormal connections, either through sprouting or by the pathological persistence of connections that exist at birth and normally disappear postnatally.

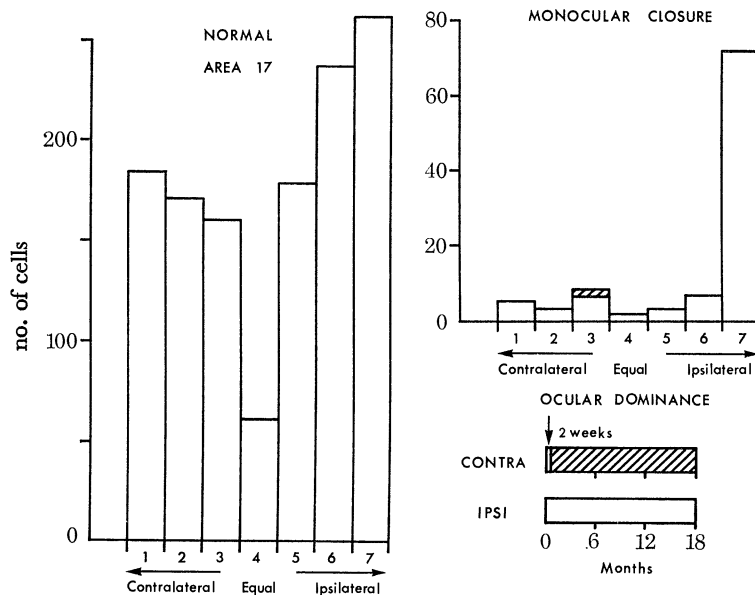


FIGURE 1. Ocular dominance histograms in normal and monocularly deprived macaque monkeys. Histogram on the left is based on 1256 cells recorded from area 17 in normal adult and juvenile rhesus monkeys. Cells in layer IV C are excluded. Histogram on the right was obtained from monkey no. 3 of the present series; the right eye was closed from 2 weeks to 18 months, and recordings were then made from the left hemisphere. Shading in histogram indicates cells with abnormal responses. (Cells in group 1 are driven exclusively from the contralateral eye, those in group 7 exclusively from the ipsilateral, group 4 cells are equally influenced, and the remaining groups are intermediate.)

In cats and monkeys deprived of vision in one eye by lid suture early in life, the cells in area 17 come to be strongly dominated by the eye that remained open (Wiesel & Hubel 1963, 1971; Baker, Grigg & von Noorden 1974). This is illustrated in figure 1 (left), an ocular dominance histogram from a series of experiments in normal adult monkeys, and (right) in a histogram from a monkey deprived by monocular suture at 2 weeks of age for a period of 18 months. The

takeover by the good eye at the expense of the bad seems to be due largely to competition between the two eyes, since closing both eyes produces effects that are far milder than would be predicted if the binocular closure were equal to the sum of two monocular closures (Wiesel & Hubel 1965). The idea that competition is involved was borne out by the effects of monocular deprivation on geniculate responses, since here the physiological changes are rather mild, possibly because at this stage the inputs from the two eyes are largely kept separate, anatomically and physiologically, with little chance for competition. There is, to be sure, considerable cell shrinkage throughout the layers connected to the closed eye, except for the monocular crescent representation, but this may be secondary to a deterioration, through competition, of terminals in the cortex, and not a direct result of a lessening of input from the deprived eye (Guillery & Stelzner 1970; Guillery 1972*a*).

In the macaque monkey, binocular convergence in area 17 is delayed beyond what are probably the first and second synaptic stages (Hubel & Wiesel 1968). Cells representing both these stages, with concentric receptive fields and 'simple' fields, are located in layer IV and are perhaps confined to that layer. The bulk of the geniculate afferents terminate in the deep part of layer IV (layer IVC), where they segregate themselves into a series of roughly parallel alternating stripes, one set connected to the left eye, the other to the right. Given the apparent lack of convergence of input from the two eyes onto single cells in layer IV, we were anxious to learn whether monocular deprivation would result in a redistribution of the afferent terminals to layer IV, or whether the boundaries would prove to be relatively immutable, as they seem to be in the lateral geniculate body. From the outset, in our studies of monocular deprivation in monkeys, we had been struck by the normality of the cortex in Nissl stains, and particularly by the absence of any hint of bands of cell atrophy in layer IVC to parallel the marked cell shrinkage in the deprived geniculate layers. This suggested that the geniculate and cortical layers were reacting in a very different way to deprivation.

We began by recording from layer IVC in monocularly deprived monkeys (lid sutured or enucleated). In addition to the technique of physiological recording there now exist three independent morphological methods for demonstrating ocular dominance columns (Hubel & Wiesel 1972; Wiesel, Hubel & Lam 1974; LeVay, Hubel & Wiesel 1975), and we were anxious to use these in examining the deprived cortex. It turned out that the physiological and the three anatomical methods all revealed very marked abnormalities, with clear evidence for an expansion of one set of columns at the expense of the other set. We also studied the distribution of geniculo-cortical terminals at birth, to learn whether the increase in the size of the columns corresponding to the open eye involved the formation of new connections or a regression of connections present at birth.

METHODS

Ten macaque monkeys were used, of which 9 were rhesus (*Macaca mulatta*) and one, no. 7, a pig-tailed macaque (*M. nemestrina*). The procedures used in these animals are summarized in table 1. Two monkeys had one eye removed at 2 weeks of age; three had the lids of one eye sutured at 2 days–3 weeks of age, and four served as controls. Results from one of the normal monkeys (no. 6) have already been published (Wiesel, Hubel & Lam 1974). In another control (no. 7), a $4\frac{1}{2}$ -year-old adult, the right eyelids had been sutured at $2\frac{1}{2}$ years of age, and reopened 6 months later; behavioural testing showed no visual defects in the eye that had been sutured, and this animal was therefore assumed, for our purposes, to be normal.

TABLE 1

no.	identifying nos. and dates	pages	figs.	procedure	age when procedure done	age studied	techniques in cortex			
							physiology	Nauta	autoradiography	reduced silver
eye removals:										
1	LM 50, 19 June 1972		2, 4 <i>b</i> , 6, 7	eye removal (rt)	2 weeks	19 months	×	×	—	—
2	LM 57, 17 Jan. 1974		3	eye removal (rt)	2 weeks	18 months	×	×	—	—
lid closures										
3	LM 58, 23 Apr. 1974 157		1, 8 <i>a</i> , 9, 11 14-18	lid closure (rt)	2 weeks	18 months	×	×	× (normal eye inj.)†	×
4	202, 23 Dec. 1974		8 <i>b</i> , 10, 19-21, 27	lid closure (rt)	3 weeks	3 weeks	—	—	—	—
5	201		22	lid closure (rt)	2 days reopened 7 weeks	7 months	—	—	× (deprived eye inj.)†	×
controls										
6	197, 28 Aug. 1973 (W. H. & L.)		—	normal	—	juvenile	—	—	× (left eye inj.)‡	—
7	186, 21 Aug. 1974		12, 13	late lid closure (rt)	2½ years reopened 3 years	4½ years	—	—	× (rt eye inj.)†	×
8	209, 30 Jan. 1975		—	normal	—	juvenile (LGB cell size)	—	—	—	—
9	230		23-25	normal	left eye inj. at 1 day	1 week	—	—	× (left eye inj.)§	—
10	243, 30 Oct. 1975		26	normal	—	8 days	×	—	—	—

† 1 mCi L-proline [2,3-³H(N)], S.A. 30-50 Ci/mmol, and 1 mCi L-fucose [6-³H], S.A. 10-15 Ci/mmol, in 100 µl normal saline.

‡ 1.5 mCi proline and 1.5 mCi fucose.

§ 2 mCi fucose.

The lids of an infant monkey are surprisingly translucent; measurements showed that they attenuate light by about 0.5 log units. The lid tissue is nevertheless cloudy enough to prevent any dark-light contours from falling on the retinas.

Brains were examined by one or more of four procedures:

(1) *Nauta method* (Hubel & Wiesel 1972). In some animals electrolytic lesions were placed with microelectrodes in single laminae of the lateral geniculate nucleus; the brains were perfused four days later, cut in frozen section at 30 μm and stained by the Nauta-Fink-Heimer-Wiitanen method (Wiitanen 1969).

(2) *Autoradiography* (Wiesel *et al.* 1974). In six monkeys, one eye was injected with 2.0 mCi of a mixture of tritiated proline and tritiated fucose or with tritiated fucose alone. The brains were perfused 14 days later, and 25 μm thick frozen sections were prepared for autoradiography.

(3) *Liesegang stain* (Le Vay *et al.* 1975). Other sections were examined by a reduced-silver stain, which has been shown to reveal ocular dominance columns in layer IV in normal juvenile or adult monkeys.

In conjunction with these special morphological procedures, every fourth section was stained by a Nissl method (Cresyl Violet), and also some of the autoradiographs were counterstained for Nissl substance. Cell size was determined in the lateral geniculate and in layer IV of the cortex by measuring cross sectional areas of neuronal somata in which nucleoli were visible. Planimetry was done on the profiles traced in camera lucida, using an *X-Y* tablet.

(4) *Neurophysiology*. Finally, most of these animals were recorded from. In the monkeys used for Nauta-degeneration studies, the geniculate lesions were placed by electrophysiological monitoring of the electrode position. On these occasions we also looked for possible abnormalities in the responses, and for any signs of spread of influence of the open eye beyond its normal territory. In the cortex, recordings were made at an acute angle to the surface, usually at 30–40°. Because of the gentle convex curvature of the exposed part of area 17, the electrode tended to become more and more tangential as it advanced, so that if ideally positioned it took a course precisely tangential to layer IV or V (see figure 3). This usually required several attempts, with the electrode either first missing layer IV completely or traversing it at too steep an angle to allow the recording of more than one eye-dominance shift. Each shift was marked by an electrolytic lesion (1 $\mu\text{A} \times 1 \text{ s}$; d.c., electrode negative). Recording procedures were otherwise the same as described previously (Hubel & Wiesel 1968).

RESULTS: PART I. EYE REMOVAL

In the first two monkeys of the present series one eye was enucleated rather than lid-sutured in order to maximize the likelihood of producing changes in the cortical columns. In retrospect such a drastic operation was not necessary, but it provided an opportunity to compare the effects of enucleation and eye closure. In these two animals the Nauta-Fink-Heimer was the only anatomical method used.

Lateral geniculate body

Physiology

Recordings were made in the lateral geniculate bodies of the two eye-enucleated monkeys (nos. 1 and 2), primarily in order to position the electrode for making electrolytic lesions in the normal and deafferented layers, but also to learn whether the deafferented layers had been

invaded by fibres from the normal eye. Without this knowledge it was obviously difficult to interpret any possible changes in the cortex.

In the geniculate contralateral to the normal eye, entrance of the electrode into the most dorsal layer was indicated by rich unit activity and brisk responses to visual stimulation. This persisted for about 0.5 mm; the electrode then suddenly entered a virtually silent region, with no hint of responses to stimulation of the normal eye and almost no spontaneous activity. As the electrode was further advanced a region of rich activity with brisk responses was again suddenly encountered, and was followed, again, by a silent region. This sequence of events of course reflected the passage of the electrode first through a normal layer, then through a deafferented one, and so on, as expected from the well-known layering pattern of the geniculate. The position of the electrode in a given layer was later verified histologically. The results suggest that there was no significant reinnervation of cells in the deafferented layers by terminals from the normal eye.

Histology

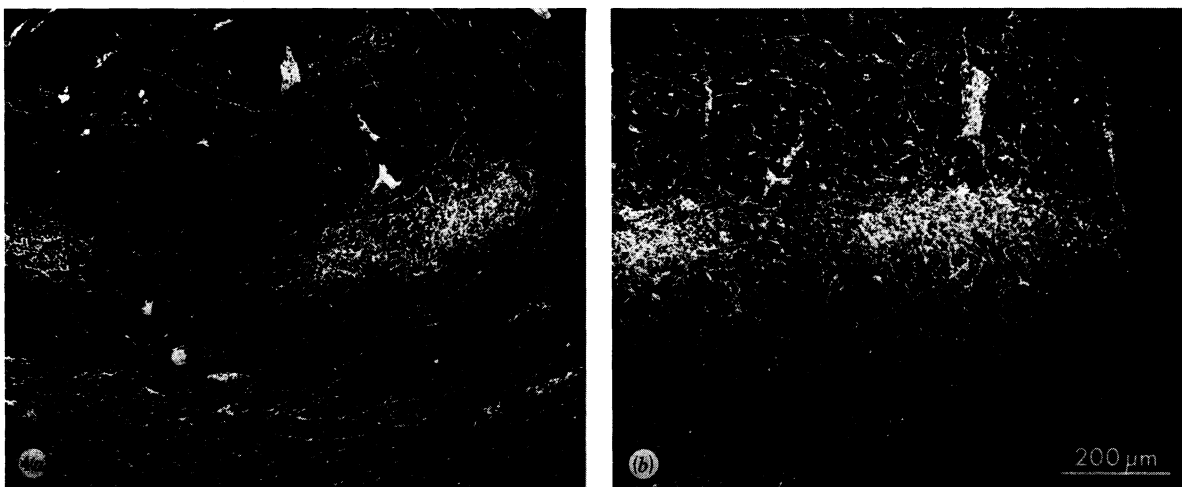
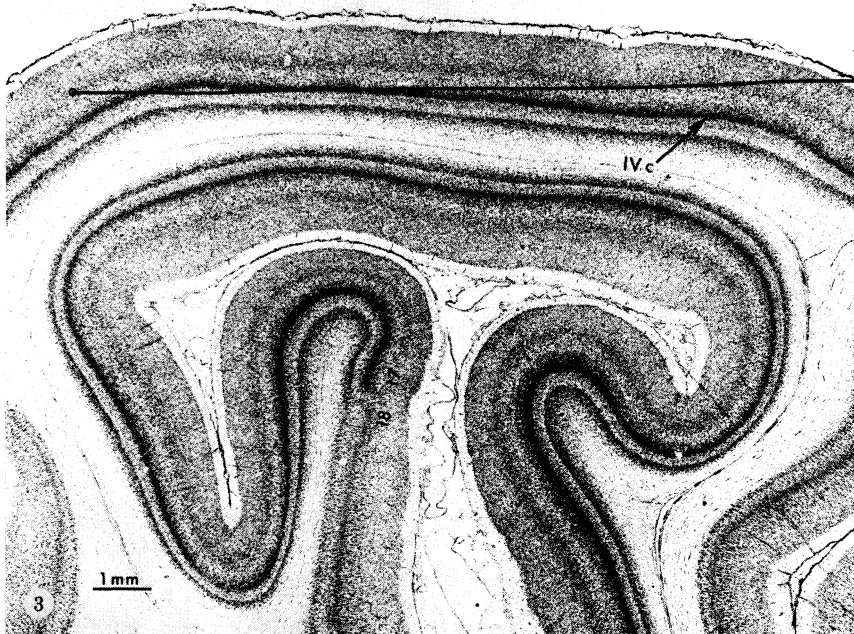
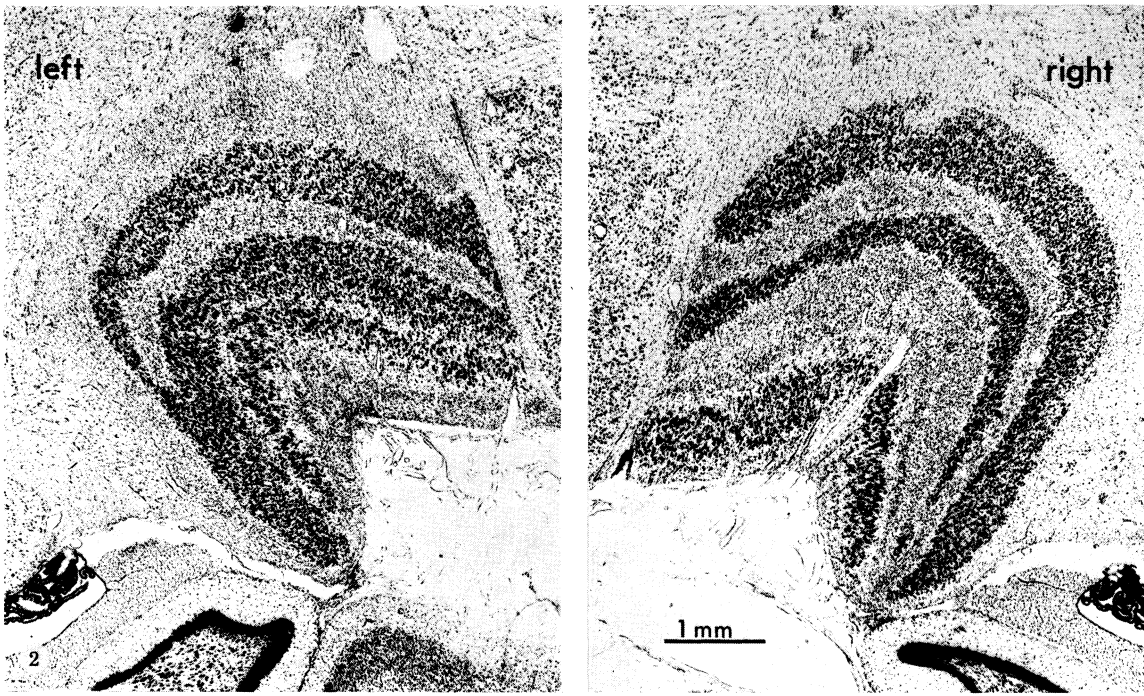
As expected from previous studies (Minkowski 1920; Matthews, Cowan & Powell 1960) there was profound transneuronal atrophy of cells in the deafferented layers. This can be seen in figure 2, plate 1, for monkey 1, whose right eye was removed at 2 weeks and the brain examined at 18 months. The results of measurements of the cross sectional areas in the normal and deprived layers in the eye-removal and eye-sutured monkeys are given in table 2; the ratio of areas in the two sets of layers (average of the two sides) was 2.80 for monkey no. 1 and 1.86 for no. 2, the large values in both cases reflecting the severity of the atrophy. (We have no explanation for the difference in these values.) The atrophy was uniform through the entire thickness of each deprived layer, with an abrupt transition from atrophic to normal at the boundaries between layers supplied by opposite eyes. This by itself suggests an absence of any extensive reinnervation of the deprived layers by the remaining eye. Both physiological and anatomical results thus indicate that enucleation shortly after birth caused a permanent deafferentation of the corresponding geniculate layers, with no extensive sprouting between layers.

DESCRIPTION OF PLATE 1

FIGURE 2. Coronal sections through lateral geniculate bodies of monkey no. 1, whose right eye was removed at 2 weeks, and the brain examined at 19 months. Brain embedded in celloidin; cresyl violet stain.

FIGURE 3. Electrode track in a tangential penetration through the left striate cortex of monkey no. 2; right eye removed at 2 weeks and the recordings made at 18 months. The electrode passed antero-posteriorly through layer IV C for a total of 3.7 mm, during which responses were continuously obtained from the remaining (left) eye. Cresyl violet. Anterior is to the right; parasagittal section. Circle at end of track indicates electrolytic lesion.

FIGURE 4. Dark-field photographs of Nauta-Fink-Heimer stained striate cortex in monkeys following lesions confined to a single geniculate layer. (a) Normal monkey, following lesion in layer 6 of the left geniculate. (monkey no. 12 in Hubel & Wiesel 1972; cf. figure 5 of present paper and Figures 7-10 in Hubel & Wiesel 1972). (b) 19-month-old monkey in which right eye was removed at 2 weeks (monkey no. 1 of present paper.) Lesion was in layer 3 of left geniculate, this layer being innervated from the remaining (normal) eye; cf. figure 6. Each photograph includes white matter, near the bottom, but does not quite reach layer I above. In *a* the band of degeneration in IV C is about equal in width to the gap between. In *b* the gap between bands is ill defined and smaller than the band to the right.



FIGURES 2-4. For description see opposite.

(Facing p. 382)

*Striate cortex**Physiology*

In the normal macaque monkey striate cortex the geniculate afferents associated with the two eyes are segregated as they terminate in the IVth layer in such a way that cells innervated by the left and right eyes form parallel alternating bands about 400 μm wide. This is the basis for the ocular dominance columns, regions in which one or other eye dominates, and which are most sharply defined in layer IVC but extend through all layers of the cortex. Thus in a typical tangential penetration the electrode moves from a region in which one eye gives the best

TABLE 2. COMPARISONS OF GENICULATE CELL SIZES AND OF CORTICAL COLUMN AREAS

monkey no.	side	layer	(lateral geniculate body 50 cells/layer)		ratio	significance†	cortex. ratio of column areas‡	
			mean area μm^2	s.d. μm^2				
1. rt. eye removal	L	6	<i>51</i> §	12	2.65	< 0.01		
		5	135	36				
	R	6	159	33	2.94	< 0.01		
		5	<i>54</i>	14				
2. rt. eye removal	L	6	<i>91</i>	15	1.87	< 0.01		
		5	170	33				
	R	6	171	28	1.84	< 0.01		
		5	<i>93</i>	12				
3. rt. eye closure	L	6	<i>128</i>	31	1.44	< 0.01	2.77	
		5	184	45				
	R	6	150	29	1.48	< 0.01	—	
		5	<i>108</i>	28				
4. rt. eye closure	L	6	<i>156</i>	33	1.26	< 0.01	1.60	
		5	197	46				
	R	6	184	37	1.20	< 0.01	1.97	
		5	<i>154</i>	36				
7. 'control' (late closure right eye)	L	6	<i>196</i>	42	1.04	N.S.		
		5	188	39				
	R	6	229	53	1.18	< 0.01		1.05
		5	<i>194</i>	48				
8. control	L	6	268	68	1.04	N.S.		
		5	258	68				
	R	6	248	70	1.12	< 0.02		
		5	<i>280</i>	54				

† Welch test. ‡ Swollen/shrunken (see table 3). § Right eye layer italics. || Larger/smaller.

responses to another in which the other eye dominates. In the IVth layer the cells are strictly monocular and their segregation according to eye input is very sharp; consequently transitions here are extremely abrupt. If there is any overlap at all, the regions must be 25 μm or less. In all our normal material we have seen no difference in widths of bands innervated by the contralateral as opposed to the ipsilateral eye: in the binocular part of area 17 (i.e. outside the representation of the temporal crescents) the two eyes seem to make almost exactly equal contributions. This equality is doubtless related to the symmetry suggested by the left histogram of figure 1, in which groups I–III are about as well represented as groups V–VII.

In the enucleated animals we were mainly interested in learning whether any changes had taken place in this arrangement of layer IVC ocular-dominance bands. If not, then in a tangential penetration one should expect an alternation between silent regions and regions of responsiveness to the remaining eye, as was found in the lateral geniculates of these animals. The results, in fact, were very different. Figure 3, plate 1, shows the reconstruction of a long (13.3 mm) tangential penetration through the striate cortex of monkey no. 2. In the layers above IV all of the cells encountered responded normally to stimulation of the remaining (left) eye. This was not entirely unexpected, since normally the majority of these cells are binocularly innervated. What was more surprising was to find that the cells in layer IV responded well to left-eye stimulation over the entire 3.7 mm during which the electrode was in that layer (3.0 mm entering the cortex, and 0.7 mm leaving). The recordings were typical for layer IVC, showing rich background activity, responsive cells with centre-surround receptive fields, and no clear tendency for the cells to prefer oriented line stimuli. There were no silent areas, only some waxing and waning of the evoked activity as the electrode advanced, perhaps more than is seen normally.

In the other eye-removal monkey (no. 1), the two penetrations in area 17 gave results that were consistent with this in showing continuous responses through the entire extent of layer IVC. The angle to the surface was too steep and the distance traversed in layer IV therefore too short to permit any conclusions to be drawn from this animal alone, but taken together, the results from monkeys nos. 1 and 2 suggested an expansion of the territory occupied by the columns of the normal eye at the expense of the set corresponding to the enucleated eye. One might, of course, explain the continuous IVth layer activity by supposing that the electrode had approached this layer in a direction almost parallel to the borders separating the bands, and had stayed in a single left-eye band throughout the entire penetration. In many previous tangential penetrations in normal monkeys we have never, in fact, recorded so long a sequence of cells dominated by one eye. In any case, the anatomical results to be described below rule out such an explanation.

Morphology

An apparent disappearance of ocular-dominance stripes in layer IVC, in physiological recordings, could conceivably be due not to a takeover by the good eye, but rather to a simple dropping out (i.e. death) of the cells in these stripes, with either an absolute shrinkage of cortex to half its surface area or a spreading out of the remaining layer IVC cells together with an associated thinning of the layer. A routine examination of the morphology of the striate cortex using a Nissl stain failed to show any hint of such changes (figure 3); the total extent of the striate cortex was normal, there was no obvious reduction in thickness or cell density in any of the layers, and layer IVC appeared uniform along its horizontal extent, with cells of normal size. In short, any reorganization had taken place in such a way as to leave no trace in routine histology.

In a previous study in normal monkeys the ocular dominance stripes in layer IV were visualized and reconstructed in serial sections by making lesions restricted to single laminae in the lateral geniculate body and later staining the cortex for degenerating terminals by a modified Nauta method (Hubel & Wiesel 1972). In any one section in these normal monkeys there were patches of terminal degeneration interrupted by equally wide patches with no degenerating terminals. Figure 4*a*, plate 1, shows an example of the cortical degeneration pattern in a

normal monkey after a small lesion restricted to the most dorsal geniculate layer. Regions of layer IVC containing terminals are sharply delineated from the terminal-free gaps, which are bridged by only an occasional degenerating afferent axon running between one zone of degenerating terminals and another. Figure 5 shows a serial reconstruction of the entire, necessarily relatively small, area of cortex containing degenerating terminals, to illustrate the characteristic striped pattern of normal ocular dominance columns, each with a width of about 400 μm (Hubel & Wiesel 1972, Figs. 8 and 10).

Similar single-layer lesions were made in both enucleated animals. Figure 4*b* shows the result of a geniculate lesion in layer 3 of monkey no. 1, on the left side, ipsilateral to (and innervated by) the normal eye. In contrast to what was found in the normal animals, the

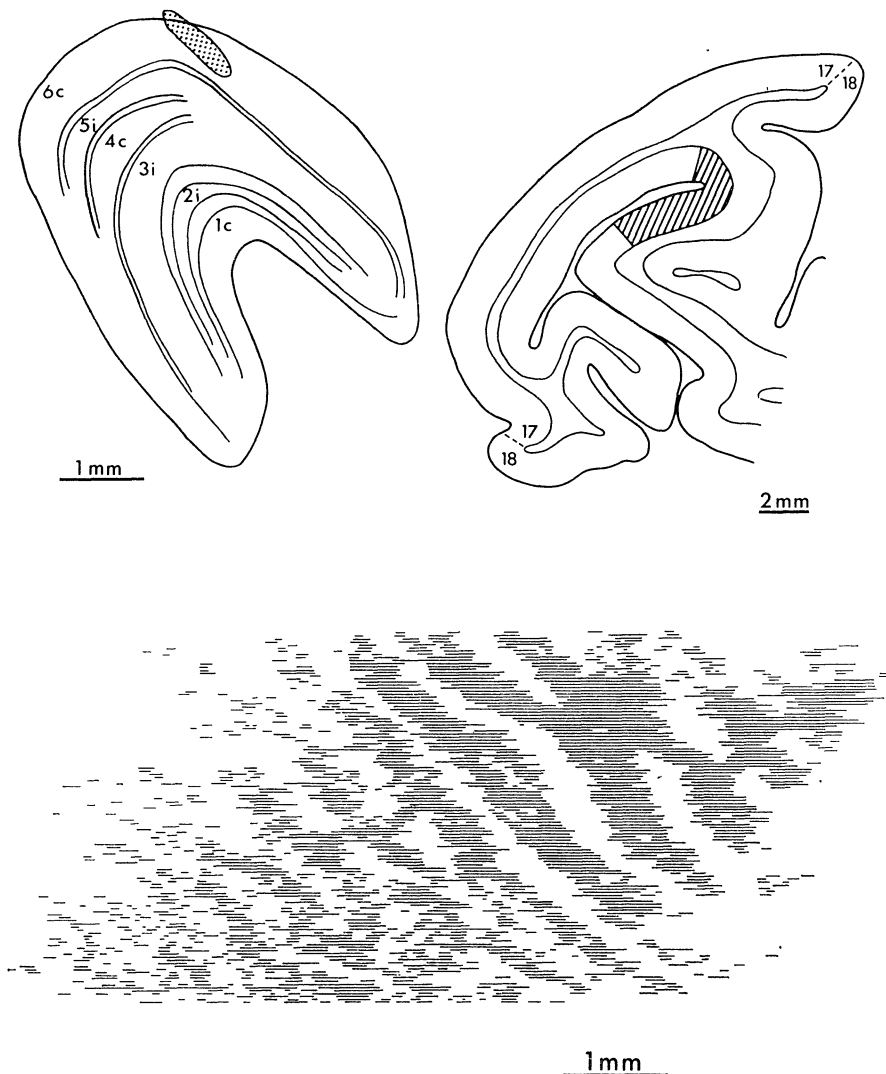


FIGURE 5. Normal monkey. Reconstruction of cortical area of Nauta degeneration, made from 121 serial parasagittal sections. The projection site in area 17, shaded in the drawing on the upper right, corresponds to the layer 6 geniculate lesion on the upper left. Each interrupted horizontal line in the reconstruction is derived from a single cortical section, by graphically straightening the shaded part of the mushroom shaped calcarine cortex, and tracing the regions of degeneration (cf. figure 4*a*). When these lines are assembled the result is a surface view of layer IVC bands, which appear as roughly parallel stripes separated by equal-size gaps, with a repeat distance of about 0.8 mm (Hubel & Wiesel 1972, monkey no. 12, Figures 8–10).

terminals in the cortex were distributed over virtually the entire region receiving input from the area of the lesion. Within this region there were variations in the density of degeneration, but gaps free of degenerating endings were only occasionally seen and were usually ill-defined and small, only a fraction of the size of the terminal-free gaps seen normally. A typical gap is shown in figure 4*b*. Except for the waxing and waning and the small gaps in terminal degeneration, the picture was reminiscent of the continuous degeneration seen after a lesion in a normal monkey involving two adjacent dorsal layers (Hubel & Wiesel 1972).

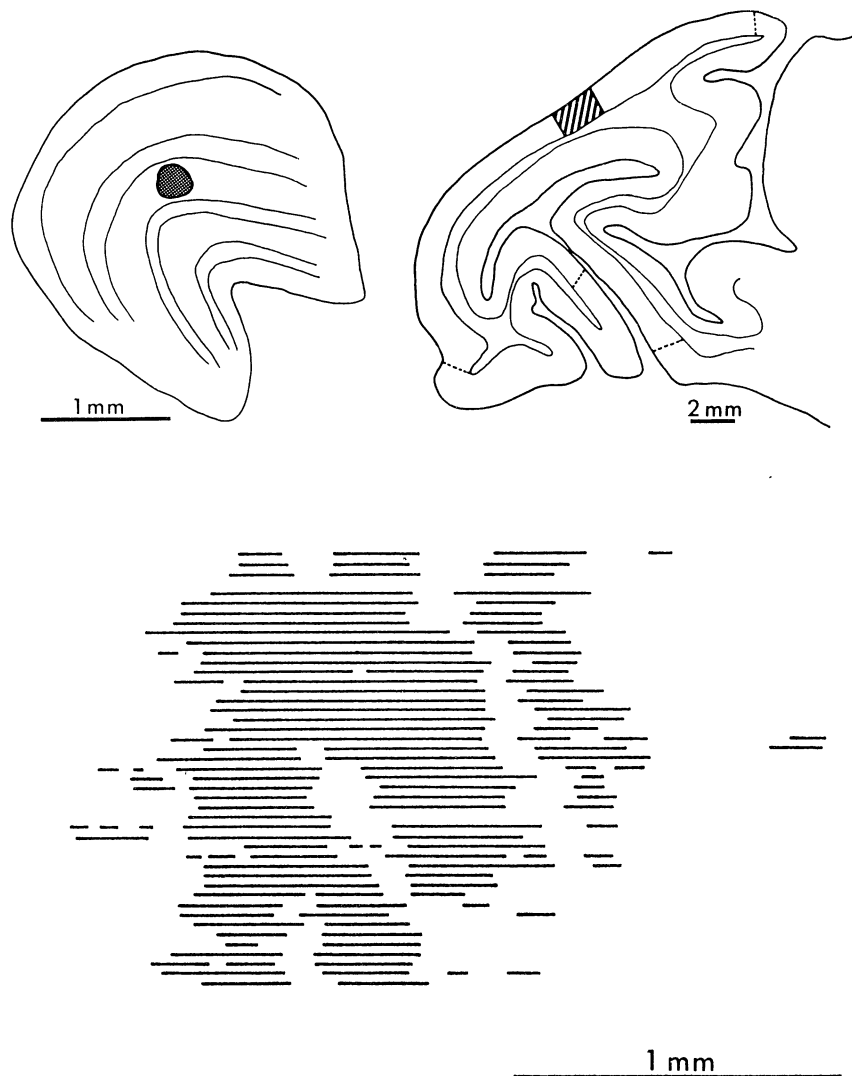


FIGURE 6. Reconstruction of an area of terminal degeneration similar to that of figure 5, but in a 19-month-old monkey (no. 1) in which the right eye was removed at 2 weeks. Lesion in layer 3 of the left lateral geniculate, supplied by the left (normal) eye. Compared with figure 5, the regions of degeneration in the reconstruction are mostly much wider and the gaps narrower, the repeat distance being unchanged.

A serial reconstruction of the entire region of terminal degeneration associated with this lesion, in monkey no. 1, is shown in figure 6. No attempt has been made to illustrate the variation in terminal density; the regions free or almost free of degenerating fragments have simply been shown as gaps. A striped pattern is strongly suggested, with a drastic narrowing of one

set of stripes and a probable widening of the other. The combined widths of the expanded and shrunken columns, assuming a 30% shrinkage in processing the tissue, is roughly 800 μm , a value close to the normal (see below).

Lesions in this monkey were also made in geniculate layer 6 on the side contralateral to the enucleated eye, i.e. a deafferented layer. The resulting degeneration in the cortex was very weak, and was confined to small narrow patches separated by wide regions with no degeneration. The picture was thus the complement of that observed after a lesion in a layer corresponding to the surviving eye. A reconstruction of one of these projection areas is shown in figure 7.

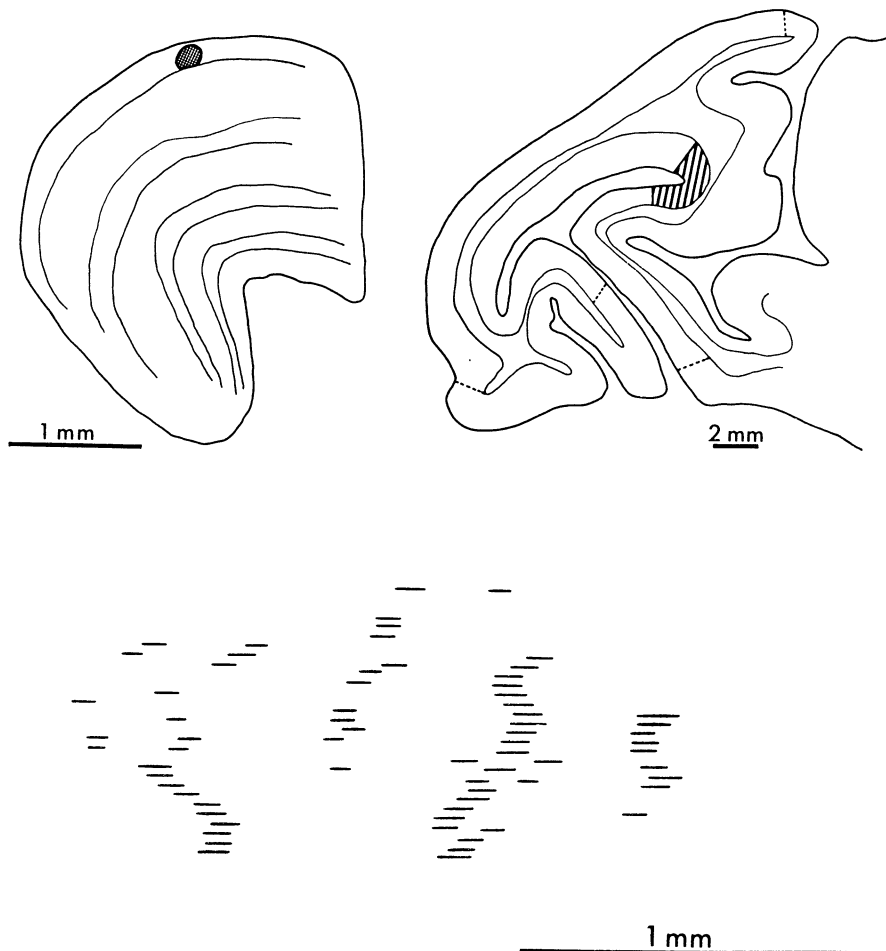


FIGURE 7. Reconstruction similar to that of figure 6 and in the same monkey, following a lesion in a deafferented geniculate layer (no. 6 on the left side). Now the areas of degeneration are shrunken and the gaps widened.

Very similar results were found in monkey no. 2 both for normal layer lesions and for deafferented layer lesions.

Thus in both the recordings and the Nauta degeneration studies it was as though the geniculate afferents serving the normal eye had invaded and virtually taken over the layer-IV territory of the enucleated eye. As Part II shows, similar results were found in animals with prolonged lid suture. Part III, however, will present evidence that casts doubt upon the notion of an invasion of one region by another, at least in any literal sense.

PART II. MONOCULAR LID SUTURE

In three monkeys (table 1, nos. 3–5) the lids of one eye were sutured closed in the first few weeks of life. Nos. 3 and 4 were expressly prepared to examine the results of long standing deprivation. No. 5 was part of a study on the time course of sensitivity to deprivation: an eye was closed from 2 days to 7 weeks and then reopened, and the animal was examined at 7 months. This monkey is mentioned in the present paper as a further illustration of monocular deprivation effects, because there is little likelihood that the reopening of the eye had any influence on the outcome.

Four control animals (nos. 6–10) are included: nos. 6 and 7 provide examples of normal cortical autoradiography; no. 7 (also part of the time-course study) had a six month period of monocular closure at $2\frac{1}{2}$ –3 years, but no abnormalities were found in a variety of behavioural tests; no. 8 was used for determination of normal geniculate cell size; nos. 9 and 10 represent a preliminary study of eye dominance columns in newborn and very young monkeys.

For the animals with eye closure two new methods were available for demonstrating ocular dominance columns, besides physiological recording and Nauta degeneration. These were, first, transneuronal autoradiography (Wiesel, Hubel & Lam 1974), in which radioactive compounds are injected into one eye and the cortex later examined autoradiographically for label transported up to layer IV of the striate cortex. The second method depends on preparing of sections tangential to layer IVC with a reduced-silver stain (LeVay *et al.* 1975). The four methods – physiological recording, Nauta degeneration, autoradiography, and reduced-silver stain – are entirely independent, relying as they do on a nerve fibre's ability to conduct impulses and on synaptic integrity, on degeneration following injury, on axonal transport, and on the ability of certain fibres to take up a particular stain.

*Lateral geniculate body**Physiology*

In monkeys with monocular eye closure one could observe responses from the deprived geniculate layers to stimulation of the eye that had been closed – something that was obviously impossible in the eye removal animals. Lateral-geniculate recordings were made only in monkey no. 3, in the course of making lesions for the Nauta degeneration studies. About a dozen cells were recorded from the deprived layers: these seemed to have normal receptive field properties, giving vigorous responses to stimulation with small spots. Transitions from normal to deprived layers and back, as judged by responses, were abrupt, with no hint in the deprived layers of any driving from the normal eye. The sample of unit recordings was obviously too small and our examination too cursory to permit any conclusions except that there were no gross physiological abnormalities, and no signs of invasion of the deprived layers by the fibres from the normal eye.

Histology: Nissl studies

Nissl stained sections through the lateral geniculate bodies of monkeys nos. 3 and 4 showed moderate pallor and shrinkage in the layers corresponding to the deprived eye. These results are thus similar to those seen by Headon & Powell (1973). Not surprisingly, the changes were far less marked than those following eye removal. The black and white photomicrographs of figure 8, plate 2, are perhaps deceptive, however, since they show the changes much less vividly than would be expected from simple inspection of the sections at low power, perhaps because

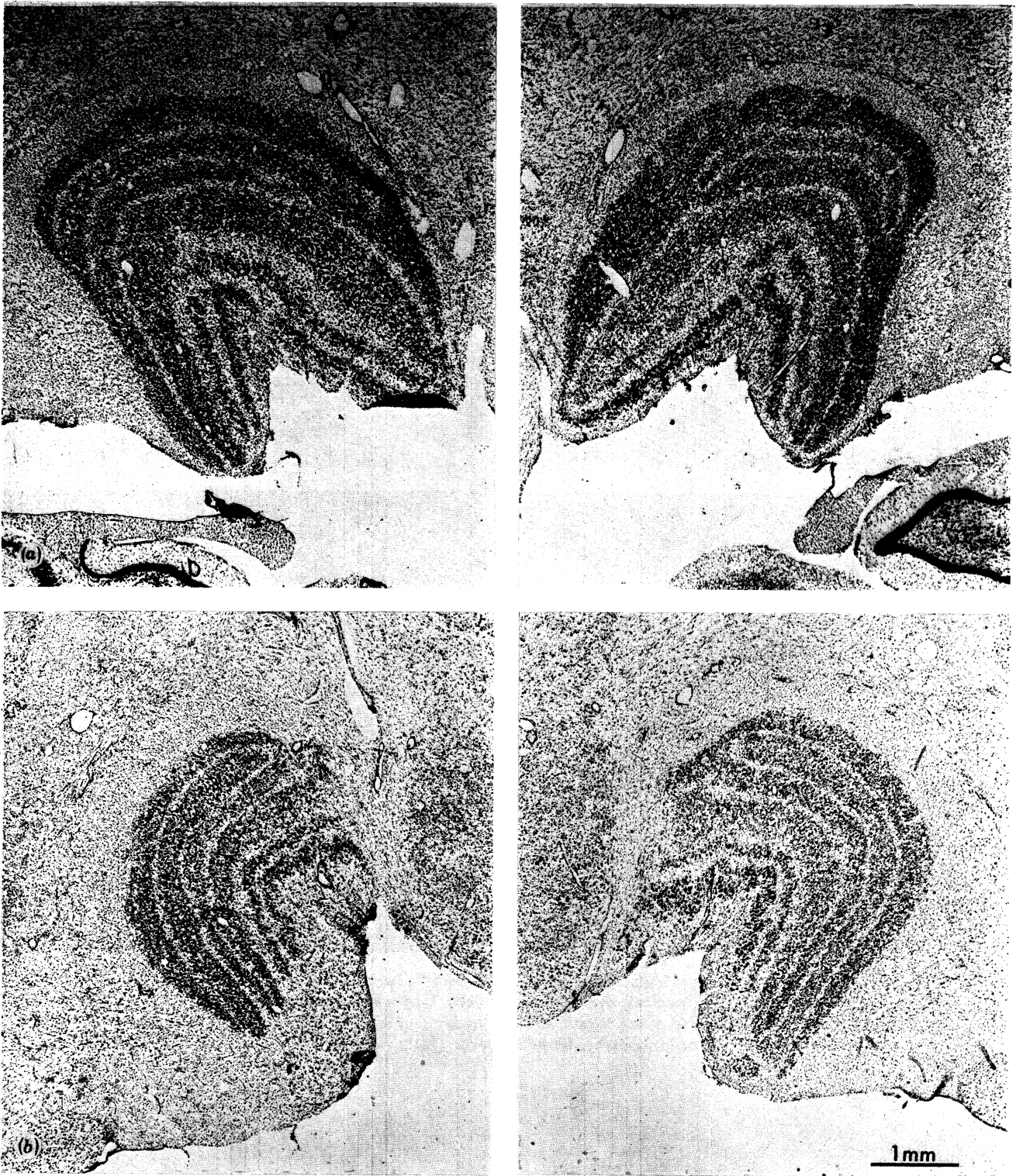


FIGURE 8. Coronal Nissl-stained sections through lateral geniculates of (a) Monkey no. 3, right eye closed at 2 weeks for 18 months. (b) Monkey no. 4, right eye closed at 3 weeks for 7 months. Note that the atrophy of the layers receiving input from the closed eye is more marked on the ipsilateral (right) side and more marked in *a* than in *b*. Cresyl violet; frozen sections.

(Facing p. 388)

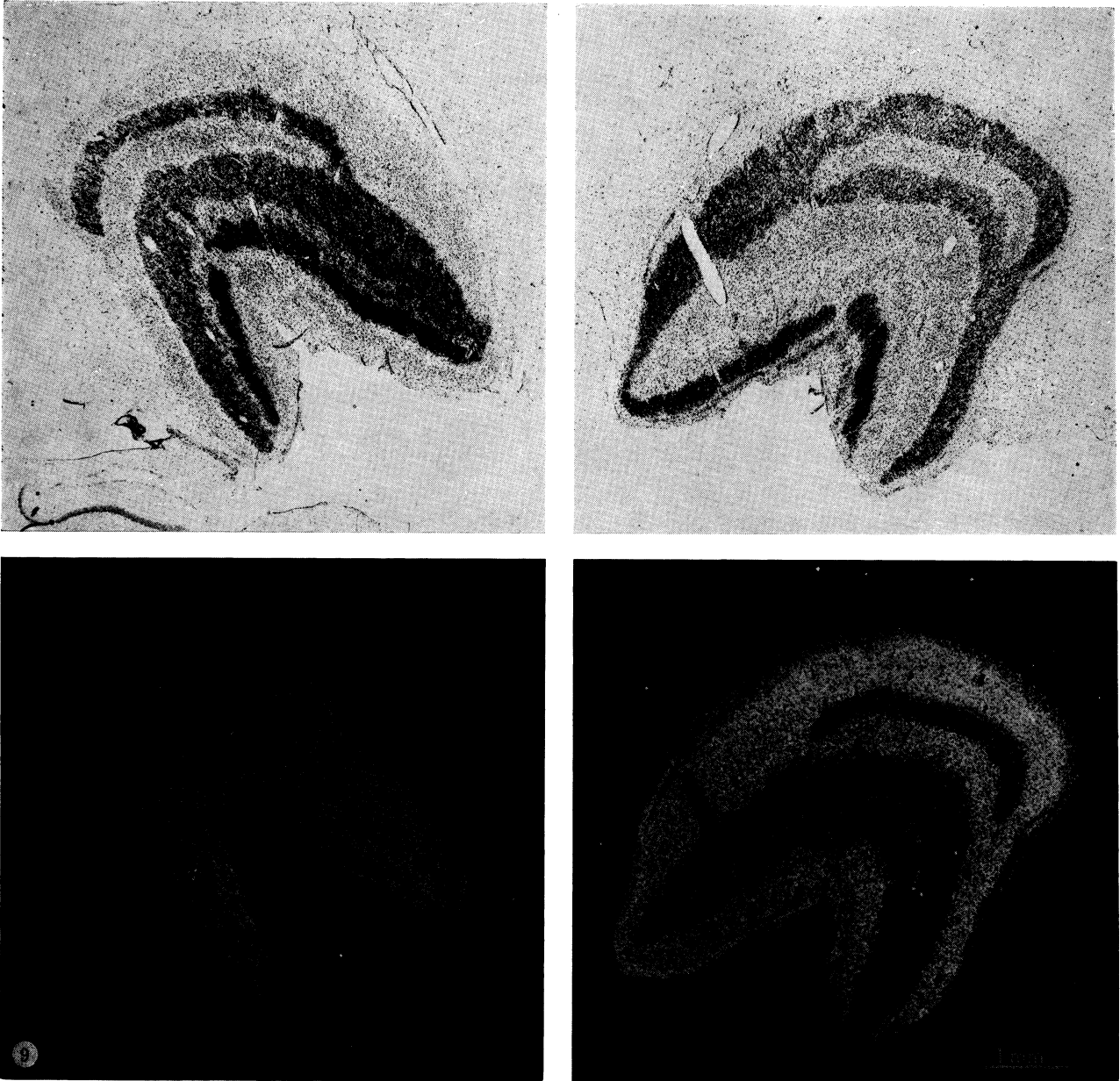
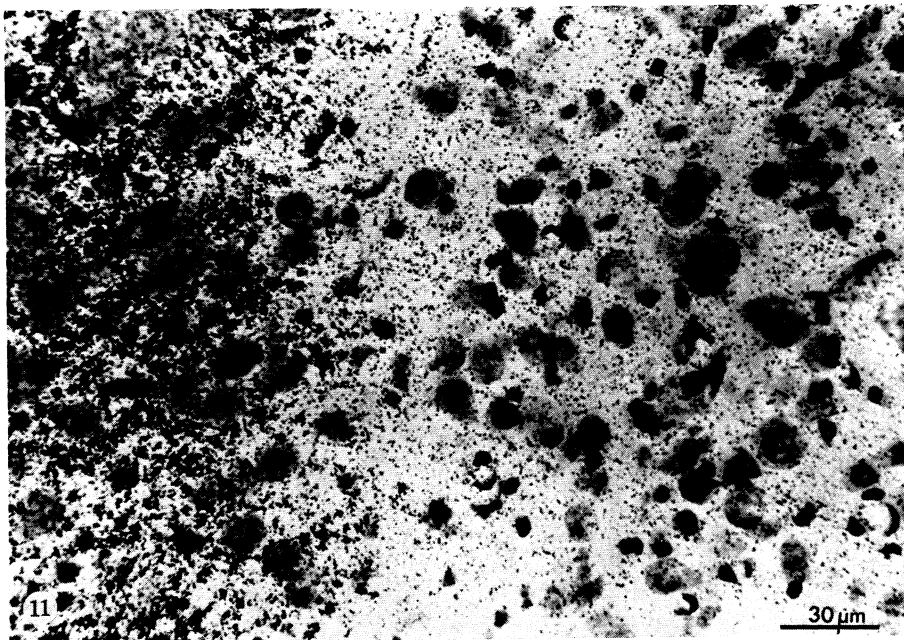
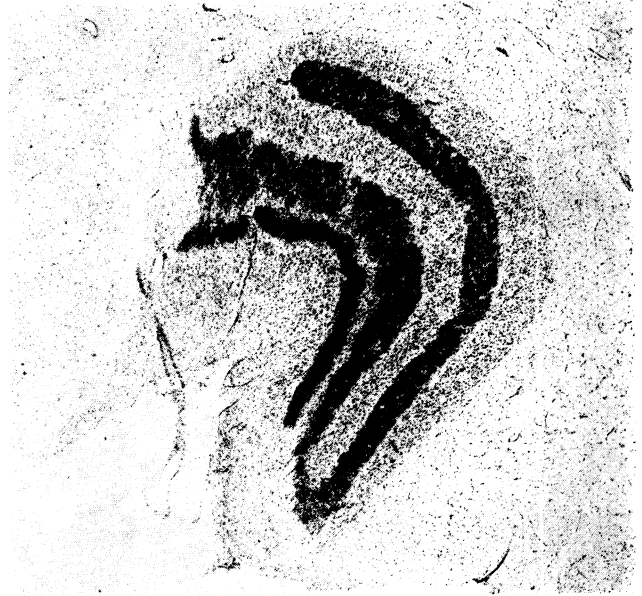
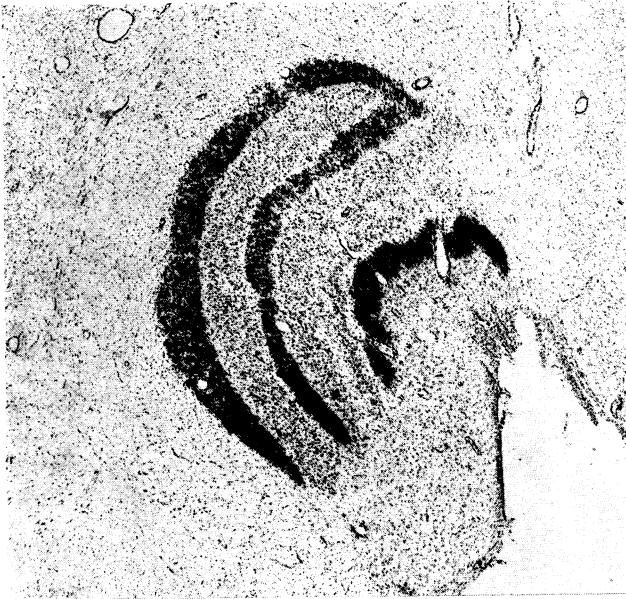

FIGURE 9. Autoradiographs of geniculates from monkey no. 3 (right eye closed at 2 weeks for 18 months) following injection of label into *left* (normal) eye. Coronal sections. Upper half, light-field, counterstained with cresyl violet. Lower half, dark-field of same sections. Note the band of label between classical layers 3 and 2, in the dark-field picture on the right (compare figure 24, layer *d*).



FIGURES 10 AND 11. For description see opposite.

(Facing p. 389)

the colours help bring out the differences in staining between normal and deprived layers. Measurements of cell size are given in table 2: the ratio of cross sectional areas in presumably normal *vs.* deprived layers was 1.46:1 for monkey no. 3 and 1.23:1 for no. 4. This is to be compared with an average of 2.33:1 for the two eye-removal monkeys.

That the deprivation effects were more severe in monkey no. 3 than in no. 4 can be seen both in figure 8 and in the cell measurements. In the cortex, as described below, the effects were likewise more severe in monkey no. 3. These differences could either be related to the week's difference in the time of eye closure or to the difference in duration of closure. Other results in the cortex of deprived and newborn monkeys suggest, however, that in eye closures lasting more than a few months the time of closure is more important than the duration.

In both of these eye sutured animals (nos. 3 and 4) the geniculate changes were most marked on the side ipsilateral to the suture – indeed, in the contralateral sections of monkey no. 4 (figure 8) it is not easy to see the changes at all. A similar asymmetry was seen by Headon & Powell (1973). Curiously, no difference between the sides showed up in the cell measurements, perhaps again because mild effects are expressed more in cell pallor than in shrinkage. A difference in susceptibility of the two sides, with more severe effects ipsilaterally, has been observed in many monkeys besides those of the present series. It also occurs in the cortical columns (see below), and there seems to be little doubt that it is genuine. (The interpretation of the apparently significant difference in a control monkey (table 2, no. 7), in cell sizes of layers 5 and 6 on the right side, is not clear.)

In describing the differences in cell size in the various pairs of layers it has been tacitly assumed that it is shrinkage in the closed-eye layers that produces the disparity. Whether there is an enlargement of cells in the normal-eye layers is difficult to determine because of the large variations in average cell size from one brain to the next, related possibly to small differences in technique. Obviously this is a question of some interest, given the increase in width of the corresponding cortical columns, to be demonstrated below.

Histology: autoradiography

In monkeys nos. 3, 4 and 5 one eye was injected with radioactive label. The resulting autoradiographs in the lateral geniculate bodies are illustrated in darkfield, in figure 9, plate 3, for monkey no. 3 and figure 10, plate 4, for no. 4. There was heavy labelling of the appropriate layers, even in monkey no. 4, whose closed eye had been injected. In both animals the label in the layers corresponding to the non-injected eye was only slightly above background levels. This is well seen in figure 11, plate 4, a higher power light-field photomicrograph from the geniculate of monkey no. 3 (normal eye injected). Here the deprived layer, to the right, showed none of the grain clumps which indicate the positions of the optic nerve terminals belonging to

DESCRIPTION OF PLATE 4

FIGURE 10. Autoradiographs from geniculates of monkey no. 4 (right eye closed at 3 weeks, for 7 months) following injection of label into *right* (lid-sutured) eye. Upper half, light field; lower half, dark field, of same sections. Counterstained with cresyl violet.

FIGURE 11. Higher power light-field view of right lateral geniculate of monkey no. 3 (compare figure 9). Layer 6 (the most dorsal layer) is to the left, layer 5 to the right, with the relatively cell sparse interlaminar leaflet between. Note the abrupt fall-off in grains, particularly in the large clumps of grains presumably representing terminals, at the boundary between layer 6 and the leaflet, indicating a lack of any noticeable invasion of the deprived layer by terminals from the normal eye.

the injected eye. Thus the autoradiography gave no indication of transgression of terminals beyond the normal boundaries. Obviously this was important in interpreting possible changes in the cortical columns.

A consistent finding in these autoradiographs of the lateral geniculate body was an accumulation of grains in several regions besides the classical 6 layers. In figure 9 one can see a bilateral accumulation of grains in a narrow band between layers 2 and 3, best seen on the left in light field, and on the right in dark field. Also there is a band of grains of contralateral origin ventral to layer 1 on the right, best seen in light field, and a clump of ipsilateral origin near the hilum, interrupting and lying ventral to layer I (left, dark field). Higher power examination suggested that the grains were mostly in terminals rather than in fibres. These additional inputs to the geniculate were not seen at more caudal levels (figure 9). They are discussed further in Part III, where similar aggregations are described in a normal newborn animal.

Superior colliculus

The distribution of optic-nerve terminals from the two eyes in the superior colliculus takes a very special form (Hubel, LeVay & Wiesel 1975). In the superficial grey, where the bulk of the input ends, the contralateral terminals tend to make up a continuous band whose lower half frequently contains cavities, and whose lower border is irregular and scalloped. The ipsilateral terminals tend to form a row of clumps which are concentrated at a level matching these holes and scallops; thus they appear to be embedded in the deep part of the contralateral input. Towards the foveal representation the ipsilateral input also comes close to the surface, in patches that appear to alternate with the contralateral input. On the whole the contralateral input probably exceeds the ipsilateral, and while the extent to which the two overlap is not clear anatomically, recordings indicate that the two eyes are not kept entirely separate.

We were curious to learn whether the eye closures had produced any changes in this patchy distribution of terminals, and especially whether there were signs of an expansion of the territory of one eye or contraction of that belonging to the other. Autoradiographs showed no hint of any changes: as in the geniculates, the distribution of terminals was normal in monkeys nos. 3 and 4. In sections counterstained with cresyl violet an examination of cells showed no hint of shrinkage or change in cell packing density in regions which from the autoradiography were known to receive input from the closed eye. Thus from the anatomical studies the superior colliculi seemed to be normal. We have not made recordings in the colliculi of deprived monkeys.

Striate cortex

Control monkeys (nos. 6 and 7): morphology

The brains of monkeys nos. 3, 4 and 7 were cut in tangential sections in the region of the exposed striate cortex (the operculum). Brains of monkeys nos. 3, 4, 6 and 7 were also cut in sections that were either parasagittal or in a plane tipped back 45° from the coronal; in most places they were roughly perpendicular to cortex, and passed through the calcarine fissure. We begin by showing autoradiographs of presumably normal cortex (monkeys nos. 6 and 7) following injection of one eye.

The transverse section from monkey no. 7, shown in figure 12*a*, plate 5, is perpendicular to the occipital operculum (i.e. to the exposed surface of the occipital lobe) and to part of the underlying calcarine fissure: almost all of the cortex in this section is striate, ipsilateral to the injected eye. Layer IV as expected shows a series of patches rich in label (brightly glowing in this

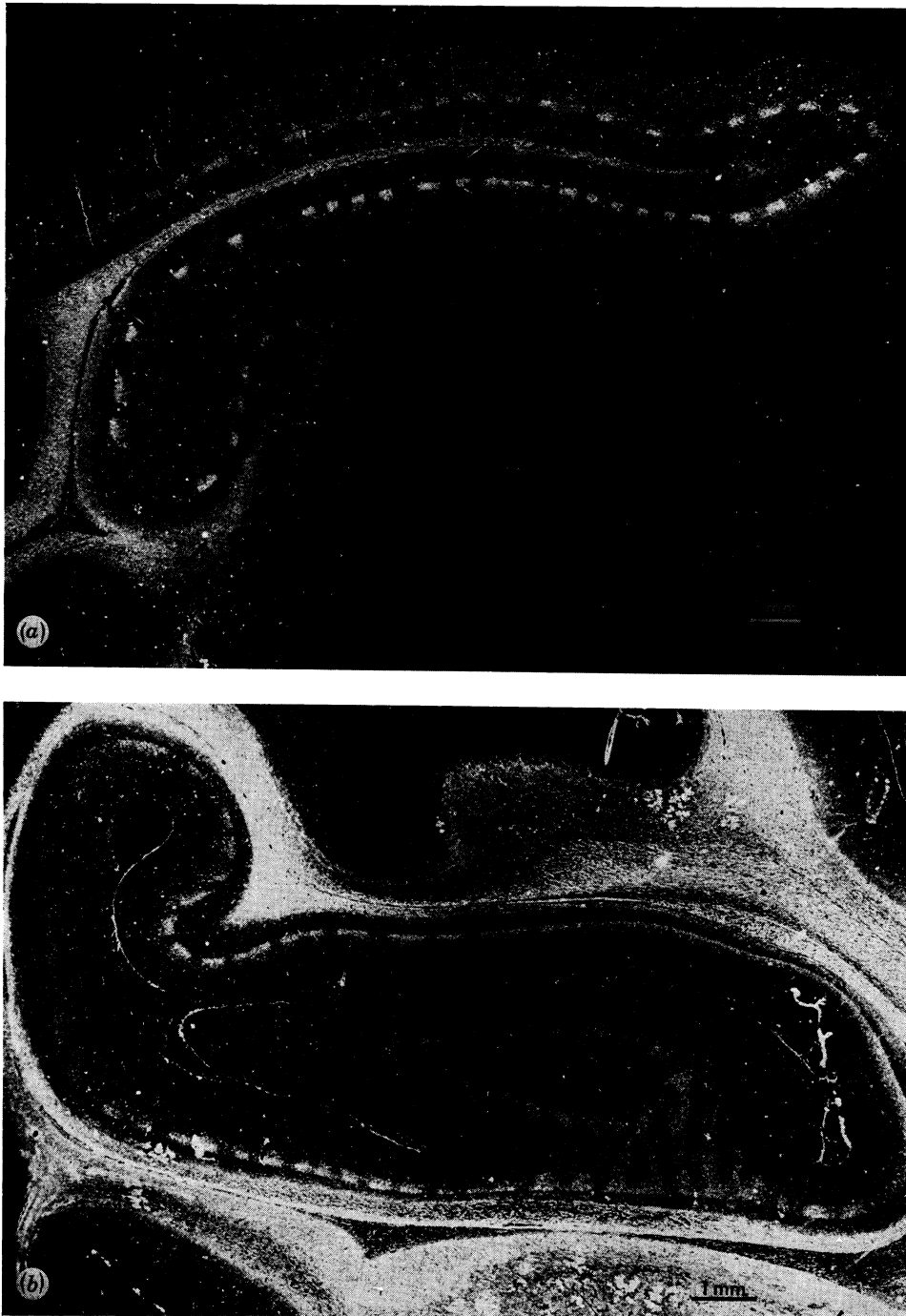


FIGURE 12. Dark-field autoradiographs of striate cortex in normal adult monkeys following right-eye injection of radioactive fucose-proline mixture 2 weeks before. (a) Transverse section through right striate cortex, perpendicular to occipital operculum, in a plane normal to the sagittal, tipped back from coronal by about 45° . Labelled bands can be clearly made out in layer IV C. In the finger-like gyrus, the opercular cortex above and the superior bank of the calcarine fissure below are separated by a brightly labelled continuous band; this represents the optic radiations. (The lower bank of the calcarine fissure has fallen away.) Medial is to the right. (Monkey no. 7.) (b) Parasagittal section through the buried calcarine cortex contralateral to the injected eye; most of the cortex is cut in a plane perpendicular to the layers, but one fold is intersected tangentially, and here the layer IV C columns are seen as parallel bands. The upper tier in layer IV A can just be made out in most places. The stretch of continuous label in layer IV C in the upper right part of the ring represents the temporal crescent. Anterior is up and to the right; the operculum would be just to the left of the figure. (Monkey no. 6.)

(Facing p. 390)

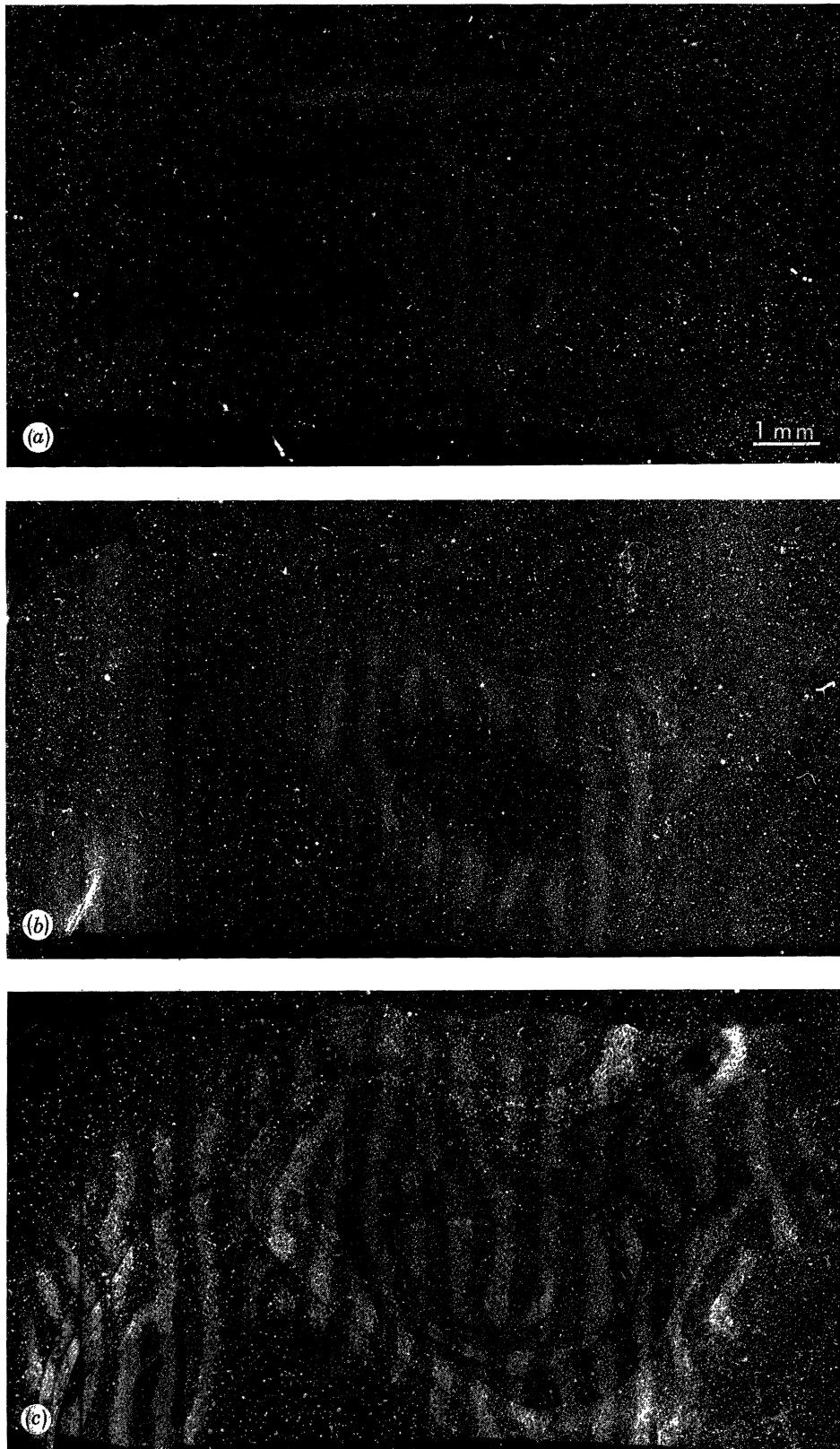


FIGURE 13. Normal monkey (no. 7). Autoradiographs taken in dark field, of tangential sections through the dome shaped exposed surface of the right occipital lobe (operculum), ipsilateral to the injected (right) eye. The section shown in (a) passes tangential to layer IV C, which is seen as a series of light stripes, representing the labelled right-eye columns, separated by gaps of the same width representing the left eye. (b) is some 160 μ m deeper than a, passing tangential to layer V and showing layer IV C as a ring of dark and light stripes into which the oval of a can be fitted. (c) is a reconstruction made by fitting together eight parallel sections including those of a and b. Anterior is up, medial to the left.

darkfield photograph) interrupted by label free gaps. In this figure about 56 pairs of columns can be counted.

Figure 12*b* shows a parasagittal section through the calcarine fissure of monkey no. 6, contralateral to the injected eye. Layer IVC is cut in most places transversely, forming a large irregular ring surrounding a smaller one, again with patches of label separated by gaps as in figure 12*a*. To the lower right the two rings join, and here IVC is cut tangentially, forming parallel stripes arranged in an oval (as occurs in figure 13). The upper right part of the outer ring of layer IVC in the figure is continuously labelled: this is the temporal crescent representation, with input entirely from the far peripheral temporal visual field of the contralateral eye.

TABLE 3. ESTIMATION OF COLUMN AREAS

monkey no.	hemi- sphere	eye injected	eye closed	combined	ratio†	shrinkage	ratio‡	shrinkage
				width		deprived		deprived
				μm		(%)		(%)
3 (157)	left	left	right	892	2.24	38	2.77	47
4 (202)	left	right	right	817	1.45	18	1.60	23
	right	right	right	831	1.61	23	1.97	33
7 (186) ('control')	right	right	(right)§	848	1.05	—	1.05	—

† Determined from small regular patches within reconstruction.

‡ Determined from virtually the entire reconstructions (figures 13, 15, 20).

§ Closed at aged 2½ years for 6 months, probably without effect.

Tangential sections through the operculum ipsilateral to the injected eye of monkey no. 7 are shown in figure 13, plate 6. The opercular cortex is dome shaped, and a plane of section that is tangential to a particular layer shows that layer as a circular patch or oval; deeper planes of section show the layer as an annulus. The section of figure 13*a* just grazed layer IVC, which appears as an oval region of alternating dark and light stripes, surrounded by the more superficial layers. Figure 13*b* is taken at a slightly deeper level, and layer IVC appears as a ring made up of stripes, surrounding the deeper layers and surrounded by the more superficial ones.

Successively deeper sections through the operculum produced larger and larger IVC rings. By photographing every second or third section, cutting out layer IVC in each and superimposing them, it was possible to reconstruct the columns over a considerable area. The result is shown in figure 13*c*. The pattern is highly regular, with a tendency for the stripes to intersect the 17–18 border at a 90° angle. This border is near the top of figure 13*c*, where the stripes end abruptly.

In this reconstruction, for comparisons with the deprived animals, calculations were made to determine the repeat distance for columns, i.e. the combined width of a left-eye column and an adjacent right-eye column. For this purpose we traced a number of regular roughly rectangular portions of the reconstruction, each containing an even number of stripes, between four and eight, avoiding areas where stripes forked or terminated. The two long edges of the block were chosen so that they fell along stripe borders. The areas of the blocks were determined by weighing. By dividing the area of each block by the total length of column pairs (number of pairs × length of block) one could estimate the repeat distance. Table 3 shows the results for monkey no. 7 and also for eye-closed monkeys nos. 3 and 4 (see below). The repeat distance for monkey no. 7 was 848 μm.

The relative areas occupied by the two sets of columns were estimated from the reconstruction of figure 13*c* by tracing the borders, cutting apart the two sets, and weighing them. The

difference in weight amounted to 5%, the contralateral set exceeding the ipsilateral (table 3, ratio†). This difference is probably not significant. Similar determinations were made from the selected regular blocks described above, with a difference again of 5% (table 3, ratio†). This figure agrees well with a similar comparison made previously using the reduced silver method in another monkey (LeVay *et al.* 1975). Thus the anatomy and physiology both suggest that in the binocular representation of striate cortex the contributions of the two eyes are about equal.

Monkey no. 3: physiology

In this monkey the right eye was closed from 2 weeks to age 18 months. The left eye was then injected. A week later 5 lesions were made in the right lateral geniculate body for Nauta studies. A week after that, finally, four penetrations were made in a direction almost parallel to the layers, in an effort to have long traverses through layer IV so that points of eye transition could be noted and marked with electrolytic lesions. In two of the penetrations (nos. 2 and 3) the tilt was sufficient so that more than one eye transition occurred in layer IV.

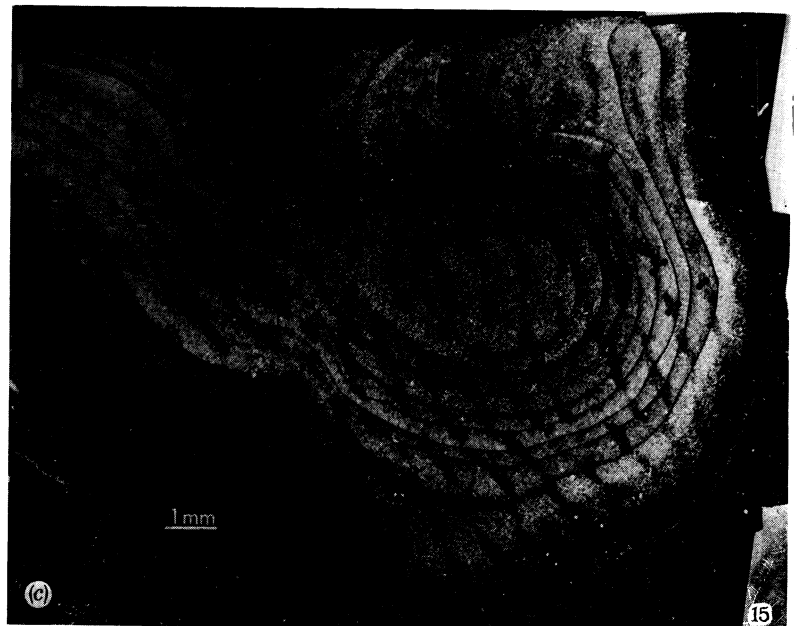
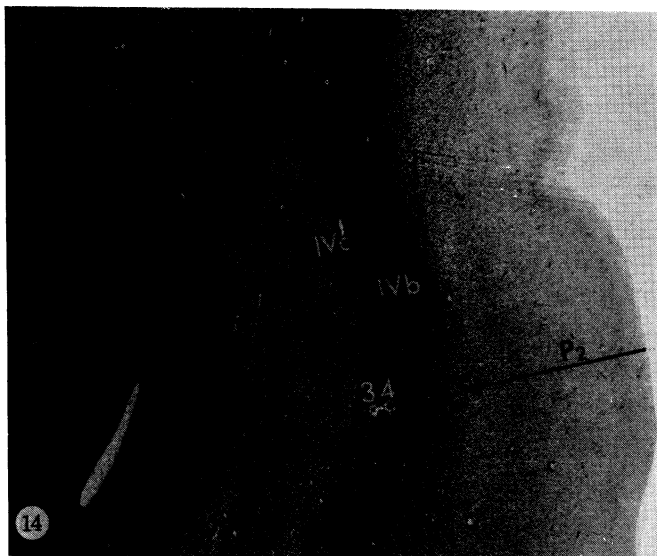

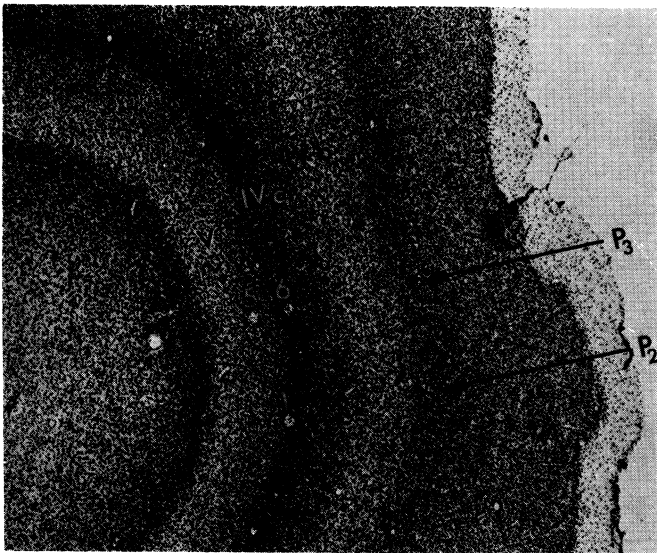

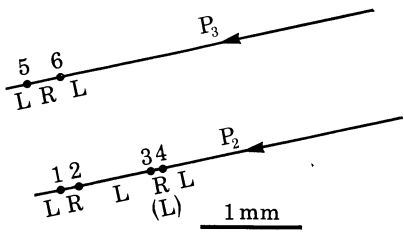
As expected from the eye-removal results and from previous work in cats, the great majority of cells were strongly dominated by the normal eye. In the layers outside of IV only about one-fifth of cells were influenced from the deprived eye, many of these weakly but with the normal orientation specificity. The ocular dominance histogram from this monkey has already been shown in figure 1. (A detailed account of the physiological properties of the cells in these animals will be presented elsewhere.)

In layer IVC, on the contrary, there were periods in which the activity was dominated strongly or completely by the deprived eye. The transitions from dominance by one eye to dominance by the other were as abrupt as in normal monkeys. In regions of domination by the deprived eye the responses seemed, surprisingly, to be quite normal, with the usual briskness and lack of any orientation specificity. These regions were nevertheless all distinctly shorter than those in which the normal eye dominated. Both the micromanipulator readings and the

DESCRIPTION OF PLATE 7

FIGURE 14. Reconstruction of two penetrations, P₂ and P₃ through the left striate cortex in monkey no. 3. Both penetrations were almost tangential to the surface, aimed in a roughly mediolateral direction through the operculum and placed 1 mm apart. (Autoradiographs and reduced-silver sections from the same region are shown in figures 15 and 17.) At the top are shown the reconstructions made from micrometer depth readings. Dots numbered 1–6 represent lesions made in layer IV while withdrawing the electrode, at the points of passing from one eye's territory to that of the other eye. L and R indicate the dominant eye where only one eye evoked responses: R(L) means that the right eye dominated but the left evoked a lesser response from the multiunit activity. Middle portion shows a cresyl-violet stained tangential section roughly in the plane of the penetrations, passing through the centre of lesion 6 and almost through the centres of 1 and 5. No. 6 is clearly in layer IV C, as were 1, 2 and 5, when the appropriate sections were examined. Lower section, a reduced-silver fibre stain (LeVay *et al.* 1975), passing through the centre of lesion 4 and just missing the centre of 3. Both are at the border of layers IV B (which contains most of the densely-staining line of Gennari) and IV C. This section is not ideally placed to show the columnar banding: a more superficial section at lower power appears in figure 17.

FIGURE 15. This figure is the counterpart of figure 13, in monkey no. 3, whose right eye was closed from age 2 weeks to 18 months. Left hemisphere operculum: (a) is tangential to layer IV C, (b) is 200 μm deeper, and (c) is the result of cutting and pasting 9 such sections, representing a total depth of 900 μm. Label in IV C, representing input from the normal eye, is in the form of swollen bands which in places coalesce, obliterating the narrow gaps which represent the columns connected to the closed eye. The thin, almost continuous belt of label in the upper tier (IV-A) is seen in all three parts. The six dots in (c) represent the positions of the six lesions of figure 14, identified on neighbouring cresyl-violet or reduced-silver sections and superimposed on the autoradiographs. The lesions are clearly at or close to the column boundaries.



FIGURES 14 AND 15. For description see opposite.

(Facing p. 392)

histological reconstruction showed that the spans in the left (normal) eye regions were 2–3 times as long as the spans in the right-eye regions. This is illustrated in figure 14*a*, plate 7, which shows the relation between penetrations 2 and 3, and the lesions made at the transition points. Both penetrations were made in the left hemisphere, from medial to lateral. The lesions were made on withdrawing the electrode so that the points of transition could be checked – hence the order of the lesion numbers. Figure 14*b* shows a Nissl-stained section almost in the plane of the penetrations and thus almost parallel to the surface, passing through the centre of lesion 6 and just missing the centres of 1 and 5. Appropriate sections through their exact centres demonstrated that lesions 1, 2, 5 and 6 were all well within layer IVC, and that lesions 3 and 4 were at the border between IVB and IVC, as seen in the fibre-stained section of figure 14*c*.

Throughout all of the left-eye (nondeprived) columns no activity could be evoked from the right (deprived) eye. In the right-eye dominated columns weak but clearly audible responses could be heard in the span between lesions 3 and 4. This is not surprising, given that these lesions were made on the IVB–IVC border, since in normal animals the eye segregation in layer IVB is not as strict as in layer IVC. In the deeper right (deprived) eye segments (1–2 and 5–6) the left eye was silent.

In summary, there were small regions within layer IV in which cells were actively driven and strongly dominated by the deprived eye, in contrast to the virtual absence of influence of that eye in the upper layers. Within layer IVC there was a striking and consistent difference in the distances the electrode travelled in the two sets of columns.

Monkey no. 3: morphology

Two neighbouring opercular sections are shown in figure 15*a* and *b*, plate 7, and a reconstruction from nine neighbouring sections including these two is shown in figure 15*c*. Confirming the results of the recordings, the labelled columns (normal eye) are very much wider than normal, and the gaps (closed eye) are very much narrower. Comparing figures 13 and 15 it is evident that the repeat distance – the combined widths of two neighbouring columns, one from each eye – is roughly the same in the two animals. Measurements made as described above for monkey no. 7 showed a combined width (repeat distance) of 892 μm , as opposed to 848 μm for the control (table 3). (Unlike the millimetre scales on the illustrations, which refer to distances on the microscopic slides, these figures have been calculated from the histology by assuming a 30% shrinkage. This is only a rough estimate based on reconstructions of electrode tracks in other animals, but the comparison is valid, provided the brains have shrunk roughly equally.) The fact that the repeat distance was apparently unchanged in monkey no. 3 is consistent with the conclusion that the expansion of one set of columns is complemented by a contraction of the other. In addition to being reduced in width the deprived columns were pinched off at irregular intervals of a millimetre or so.

The relative areas occupied by the labelled columns and the gaps were estimated by the methods outlined above for the normal. Taking the entire reconstruction and cutting apart the left-eye and right-eye regions the result was a ratio of 2.77:1 for labelled columns to unlabelled ones, as compared with 1.05:1 for the normal (table 3, ratio†). The ratio from selected regular blocks, calculated as for monkey no. 7 (table 3, ratio†), was lower, amounting to 2.24:1. The lower ratio presumably resulted partly from the omission of pinched off areas, in selecting these blocks.

We found that electrolytic lesions of the rather miniscule size necessary to mark the points of transition from one eye to the other, in the physiological recordings, were impossible to identify in dark-field autoradiographs. They were easily found, however, in the Nissl and reduced-silver sections that were interspersed between the autoradiographs (see figure 14), so that comparison of adjacent sections made it possible to determine their precise position on the autoradiographs, with respect to the column boundaries. These are marked in figure 15*c*.

An autoradiograph through the calcarine fissure (figure 16, plate 8) likewise showed gaps, between labelled regions, that were markedly shrunk and in places almost obliterated. The section is taken from the side ipsilateral to the closed eye. Though it is difficult to compare the severity of shrinkage on the two sides, given the difference in planes of section, our impression from this and other examples is that deprivation effects were more marked on the side ipsilateral to the closed eye (compare figures 21*a* and 21*b*).

The reduced-silver stains gave results that faithfully paralleled the autoradiographs and the physiology. The bands corresponding to columns in layer IV could be seen only in tangential or very oblique sections, and were seen best at very low power in the upper part of IV C, just beneath the line of Gennari. In figure 17, plate 8, an alternation of wide (W) and narrow (N) dark bands can easily be seen. The narrow bands were clearly identified as corresponding to the deprived columns, and the wide bands to the non-deprived, by noting their positions with respect to the lesions in penetrations 2 and 3, and to the columns as shown in the autoradiographs.

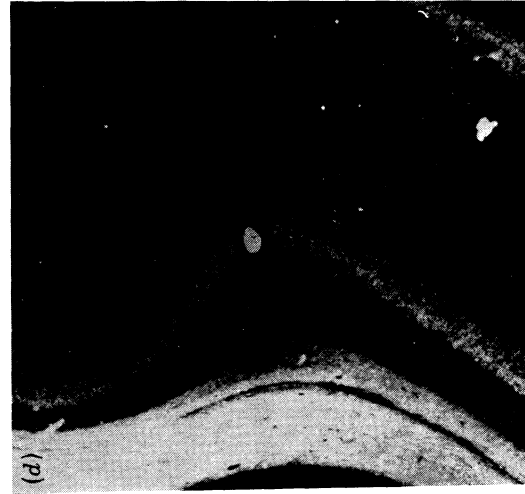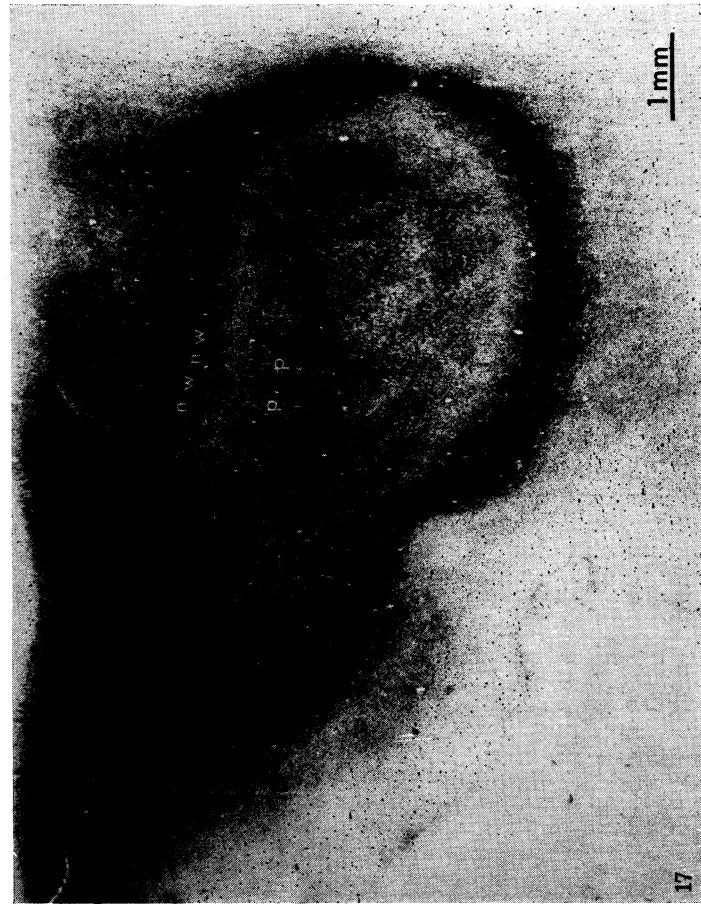
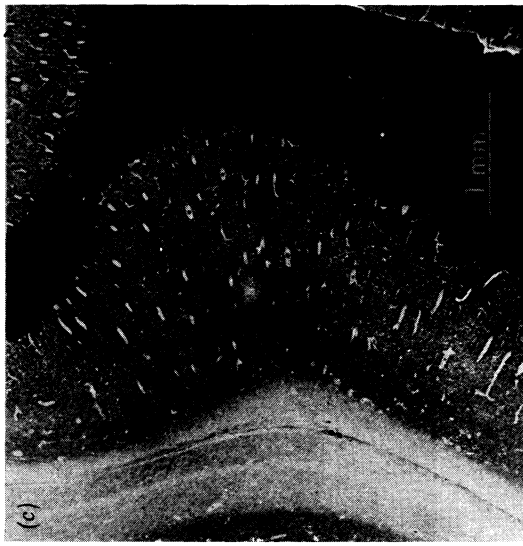
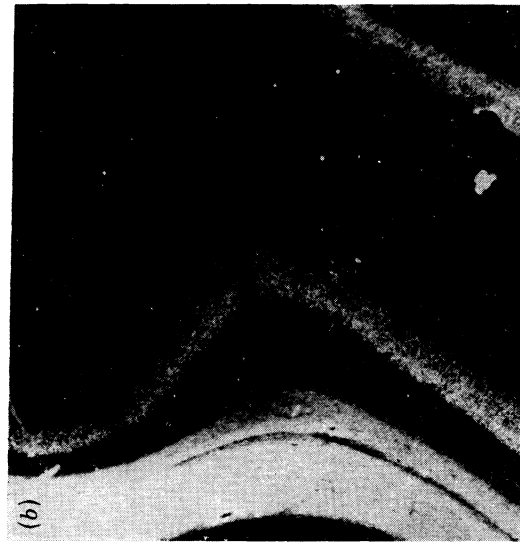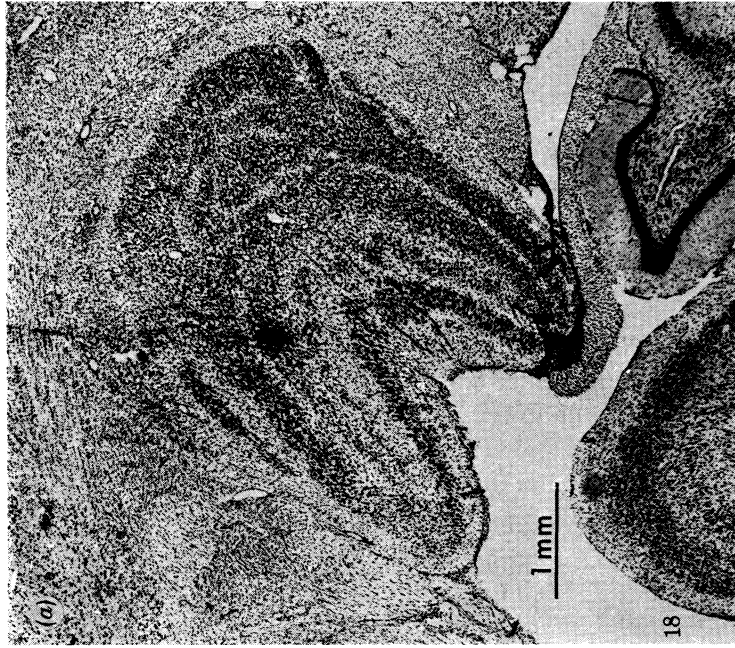
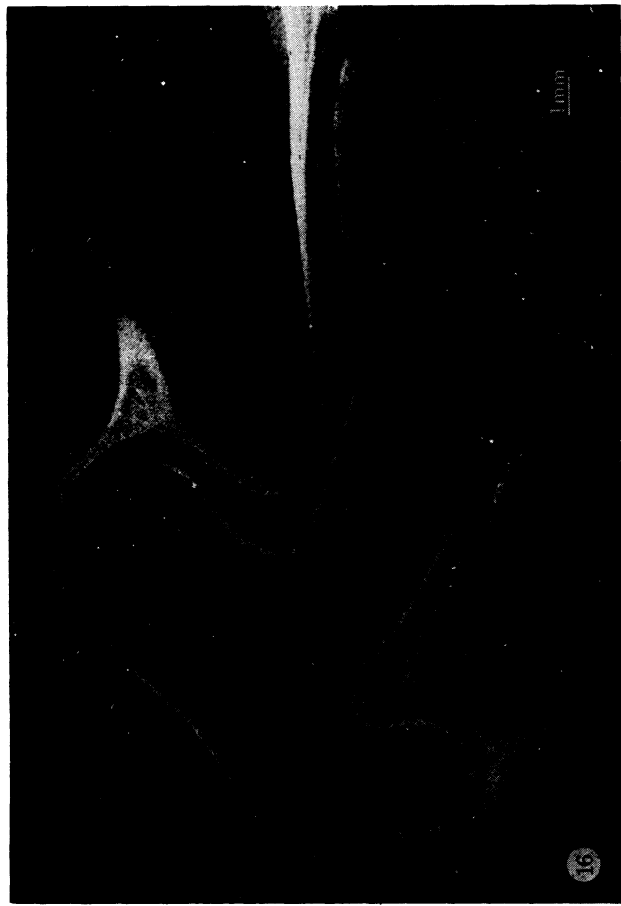
Another abnormality observed in the reduced-silver sections was the appearance of broad pale bands (P) in layer V, where normally no banding is visible. These bands, which stand out clearly in the central part of figure 17, were in register with the set of shrunken ocular dominance columns just above, in layer IV C. Similar bands could be seen, though less clearly, in

DESCRIPTION OF PLATE 8

FIGURE 16. Monkey no. 3; right eye closed from 2 weeks to 18 months. Left eye injected. Dark-field autoradiograph through right calcarine cortex. Over the mushroom, label representing input from the contralateral (normal) eye has almost obliterated the gaps, representing the deprived eye, and greatly narrowed them even where they are best preserved, in the dorsal stem. Anterior is up and to the right.

FIGURE 17. Monkey no. 3. Reduced-silver stained section parallel to those of figure 15, and 40 μm deep to the section of figure 15*b*. The Gennari Line, layer IV B, appears as the most densely stained black ring. Dark bands corresponding to the layer IV C columns are best seen in the most superficial part of IV C, i.e. just deep to IV B or the Gennari Line – in this section just inside the dark ring. These bands are alternately wide (W) and narrow (N). In autoradiographs neighbouring this section, such as the one shown in figure 15*b*, the labelled (bright) columns were found to correspond precisely to the wide bands and the unlabelled (dark) gaps to the narrow bands. Still further inside the Gennari ring is a prominent light area, the cell-dense part of layer IV C; within this is layer V, with its pale bands (P) in register with the narrowed dark bands of IV C (N).

FIGURE 18. Monkey no. 3. The results of making a lesion in the right lateral geniculate nucleus, confined to layer 3, a layer corresponding to the closed eye. The lesion and electrode track are shown in the cresyl-violet section in *a*. The resulting Nauta degeneration was deep in the calcarine fissure, no more than one or two small patches occurring in any one section. One such patch of terminals is shown in the dark field photograph in *c*. The next section to this was dipped for autoradiography, with the result shown in *b*: here layer IV C is almost continuously labelled except for a narrow gap at the knee where the calcarine stem joins the mushroom. Sections *b* and *c* were superimposed, and in *d* the region showing Nauta degeneration is indicated by white, in the autoradiograph. The two regions match precisely, except that the Nauta degeneration appears only in bottom half of IV C (IV C β), as expected following a parvocellular geniculate lesion.



FIGURES 16-18. For description see opposite.

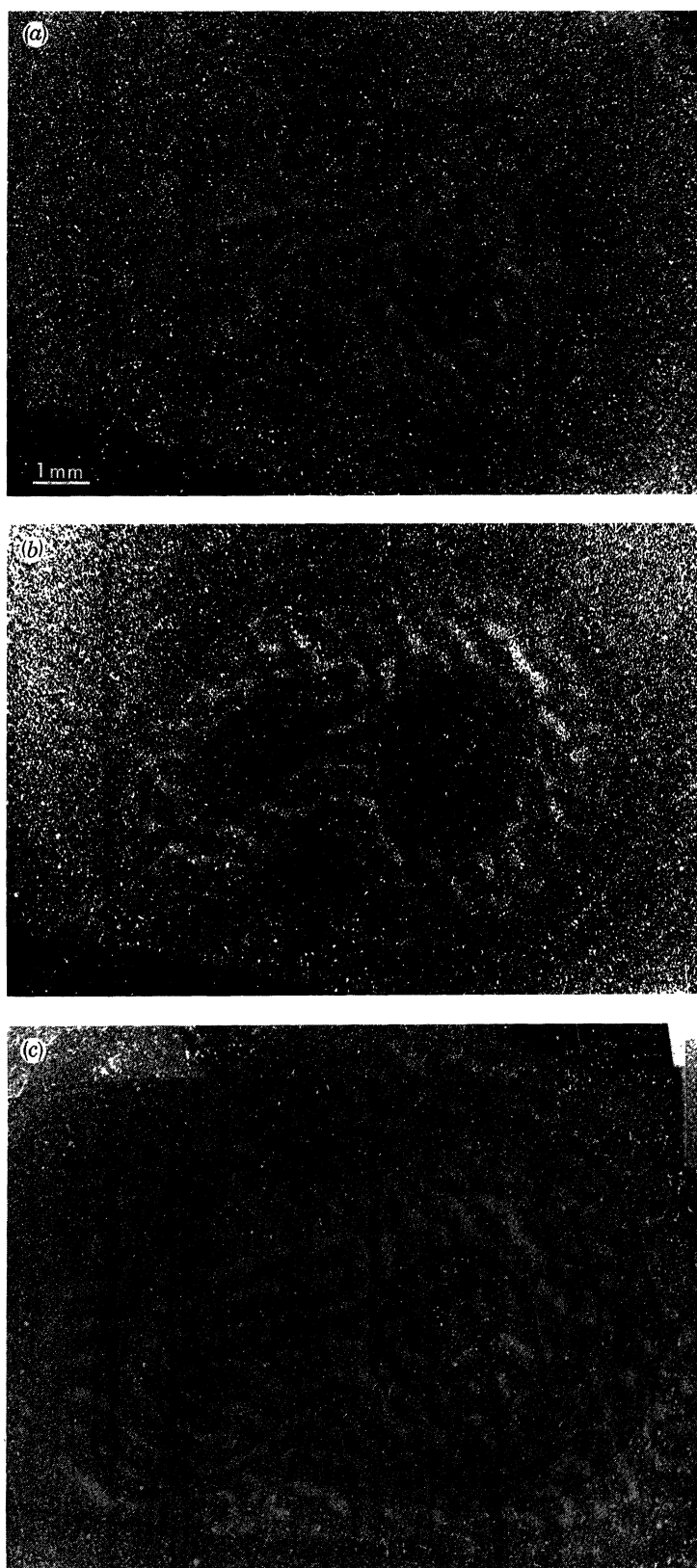


FIGURE 20. This is the counterpart of figures 13 and 15, for monkey no. 4; right eye closed at 3 weeks, until age 7 months; right eye injected. Dark-field autoradiographs of right occipital operculum. (a) tangential to layer IV C; (b) 120 μ m deeper than a, tangential to layer V and intersecting it twice because of dimple in cortex. (c) reconstruction made up of 7 sections including a and b; total depth 640 μ m. The labelled columns, corresponding to the closed eye, are markedly shrunken.

layer III. Close inspection of layer V showed that within the pale bands the tangential fibres were of abnormally fine calibre. The tangential fibre plexus of layer V consists largely of collaterals of the descending axons of layer III pyramidal cells (Spatz, Tigges & Tigges 1970; Lund & Boothe 1975). These observations thus suggest a deterioration of descending connections between layers III and V within the deprived-eye columns.

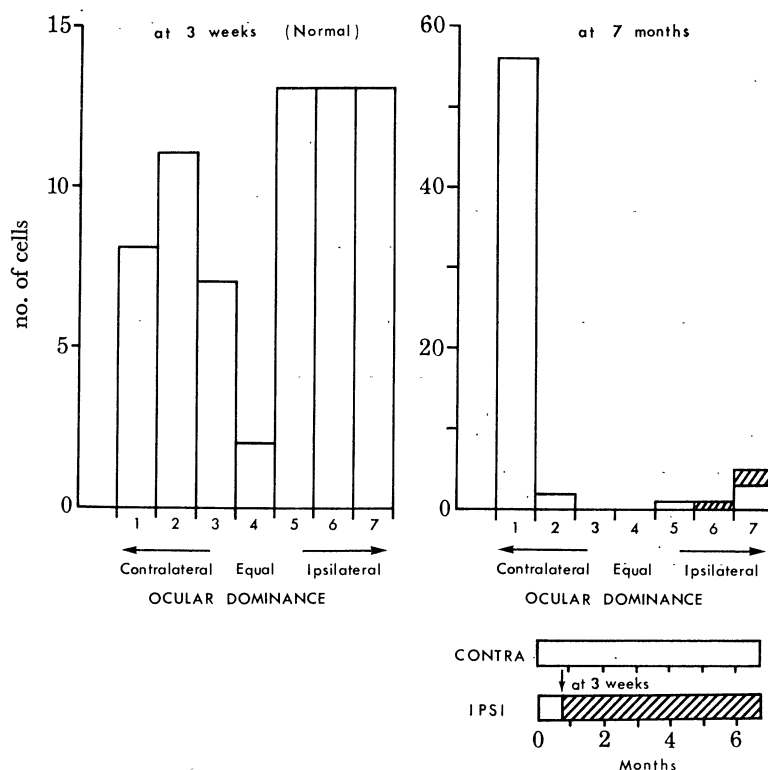


FIGURE 19. Ocular dominance histograms from striate cortex of monkey no. 4, at 3 weeks, when the right eye was closed, and in a second recording session at age 7 months. The histogram at 3 weeks (right hemisphere) is similar to the adult histogram (figure 1). After the deprivation the histogram is as expected strikingly abnormal, and almost identical to that of monkey no. 3 (see figure 1). Here four penetrations were made, three on the right side and one on the left. 'Ipsilateral' refers to domination by the right (deprived) eye. Shading in histogram indicates cells with abnormal responses.

Finally, we were anxious to determine the degree of overlap (if any) between the widened and the apparently narrowed columns of this animal. The recordings, as described above, indicated that the deprived-eye columns were reduced, and no activity was evoked from the deprived eye in the normal-eye columns in layer IVC, suggesting that there was little or no overlap. Autoradiographs from normal-eye injections by themselves could obviously prove nothing about the width of the stripes corresponding to the closed eye, and we wished to confirm morphologically the impression from the physiology-plus-lesions (figure 14, 15*c*) that the gaps in the autoradiographic picture did actually represent the deprived-eye columns. Two studies in which deprived eyes were injected support this contention (see below), but for more direct evidence Nauta studies were made in monkey no. 3, and the results were correlated with the results of the autoradiography.

Five geniculate lesions were made in the hemisphere ipsilateral to the removed eye, 1 each in layers 1, 3, and 4, and two lesions in layer 6, and for three of these lesions the corresponding

regions of degenerating terminals in the cortex were found. Figure 18*a*, plate 8, shows a lesion in geniculate layer 3, which receives input from the closed eye, and figure 18*c* (lower right) a Nauta-stained section from the corresponding region in the calcarine fissure. A single focus of degenerating terminals is conspicuous deep in layer IVC (arrow). This could be followed in neighbouring sections, and represented a wormlike structure 150 μm wide, extending some 400 μm in a direction normal to the plane of the section.

An autoradiograph made from the section immediately neighbouring that of figure 18*c* is shown in figure 18*b*. The gap between labelled columns corresponds precisely to the region of terminal degeneration (figure 18*d*), providing a welcome mutual confirmation of the two methods. The fact that the space taken by degenerating fibres in the Nauta section and the size of the gap in the autoradiograph were roughly the same suggests, as had the recordings, that there was little if any overlap between the inputs from the normal and abnormal eyes.

Figure 18*d* shows that the terminal degeneration in layer IV following this dorsal-layer geniculate lesion was confined to the deeper half of layer IVC (IVC β), in agreement with what was found in a previous study (Hubel & Wiesel 1972). The radioactive label following eye injection of course occupied the full thickness of IVC, since both dorsal and ventral geniculate layers were involved in the transport.

The remaining lesions were made in geniculate layers corresponding to the open eye. In all of these the corresponding degeneration in the cortex resembled that found in the eye-removal monkeys (figure 6) and was present only in portions of layer IVC which, in the autoradiographs, were occupied by silver grains.

Monkey no. 4: physiology

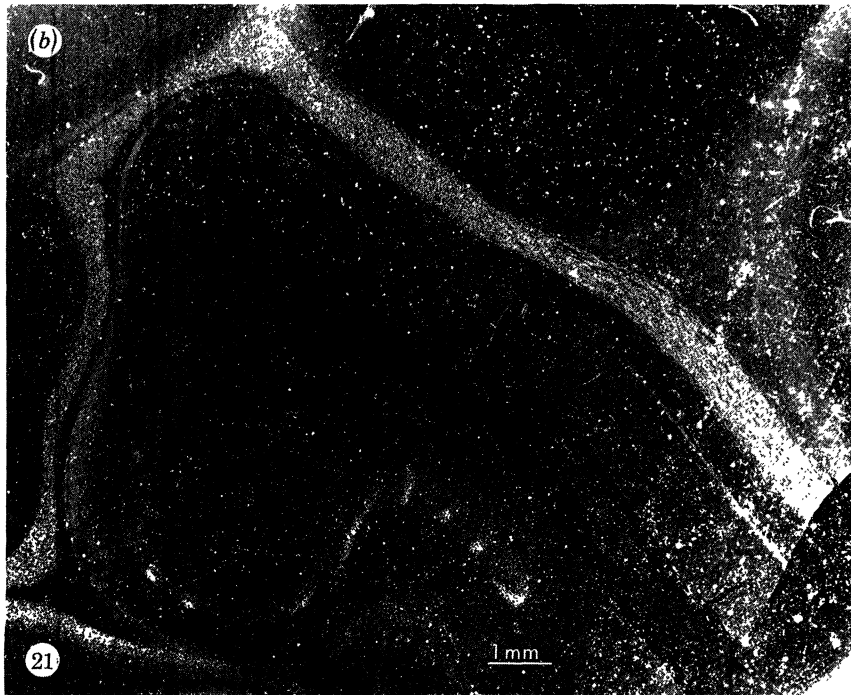
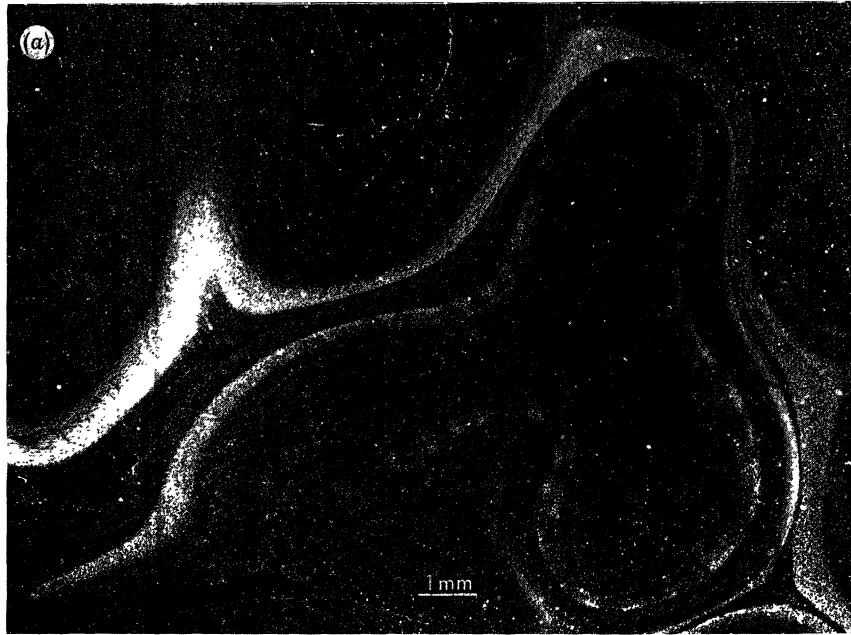
The right striate cortex of this monkey was recorded from twice, at 22 days, at which time the right eye was sutured closed, and then at 7 months, after just over 6 months of deprivation. On the first occasion 66 cells were recorded in two penetrations. The ocular dominance histogram was entirely normal by adult standards, as may be seen by comparing the histogram from these two penetrations (figure 19) with that of figure 1 for the normal adult. The results of this recording session will be described in more detail in Part III.

The ocular-dominance histogram at 7 months is shown to the right in figure 19. Four penetrations were made, all tangential. Again, cells from layer IVC are not included. (We wished to study layer IV in detail, and therefore recorded as many cells as possible from it. The inclusion of these cells would have greatly increased the number of cells in groups 1 and 7.) The pronounced effects of the eye closure on the upper and lower layers is obvious, as can be seen by comparing the two parts of the figure.

DESCRIPTION OF PLATE 10

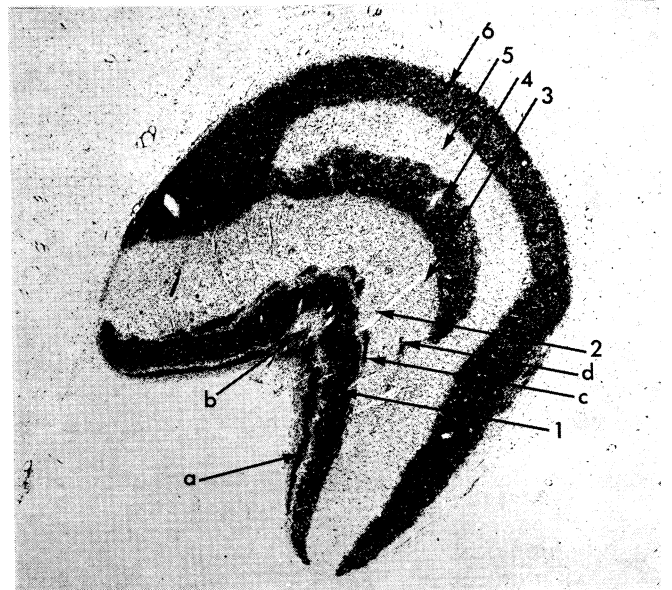
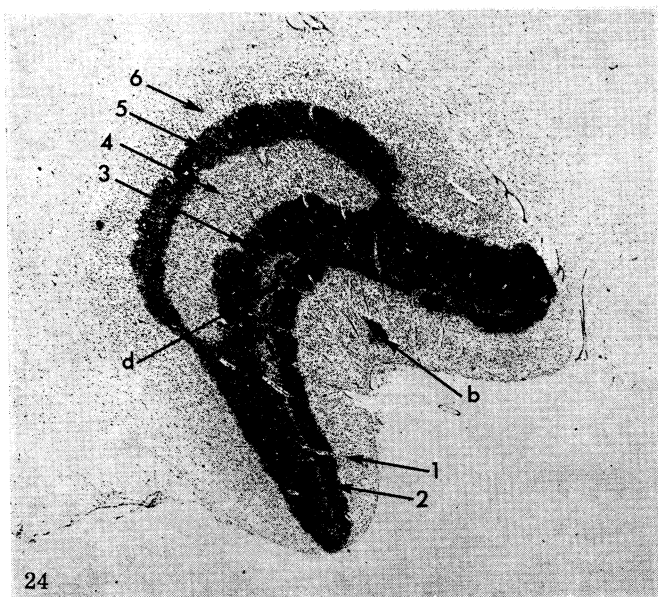
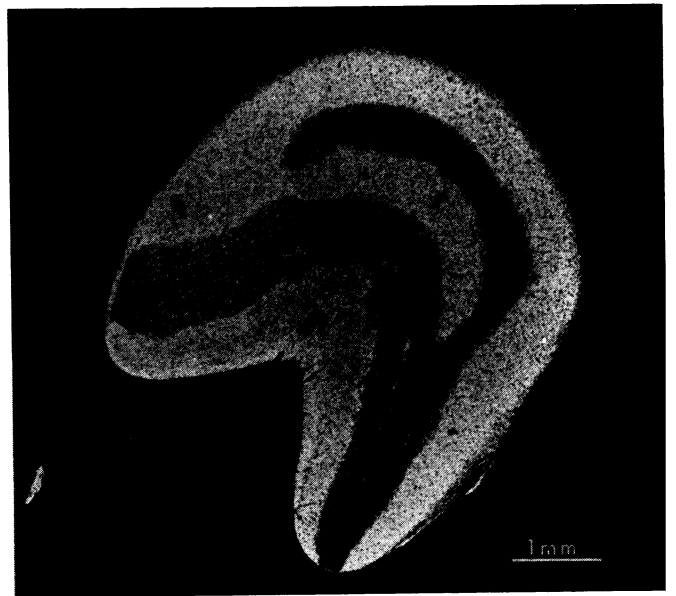
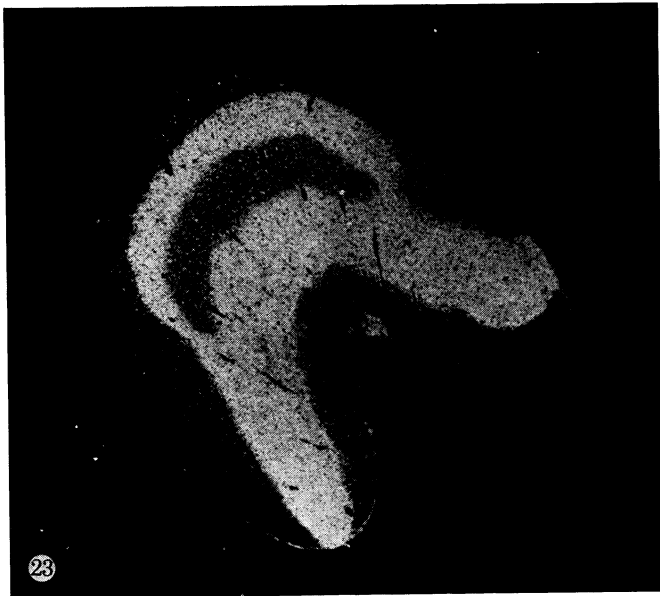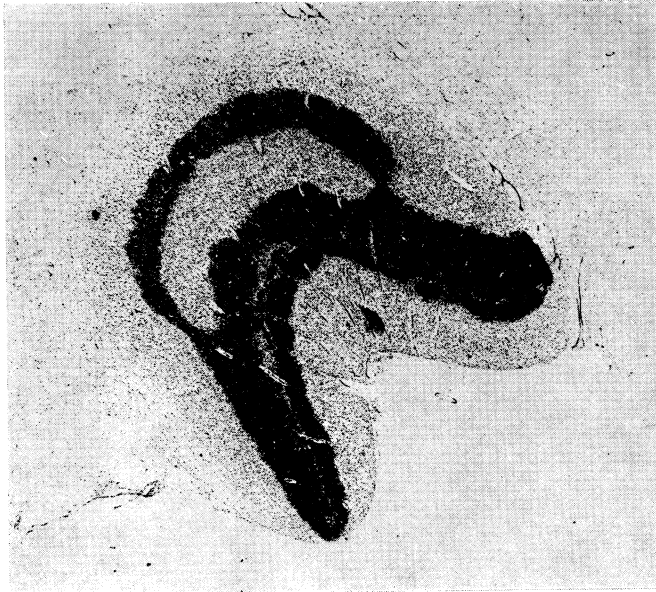FIGURE 21. Monkey no. 4, dark field autoradiographs through calcarine cortex, (*a*) contralateral to the closed, injected eye, (*b*) ipsilateral to the injected eye. Note that the deprived columns are more severely shrunken on the ipsilateral side. The temporal-crescent representation is very conspicuous in *a*, and seems not to be affected at all.

FIGURE 22. Monkey no. 5; right eye closed at 2 days for a period of 7 weeks, then reopened up to the age of 7 months, when the right eye was injected and the brain examined 2 weeks later. Dark-field autoradiograph, transverse section through ipsilateral calcarine fissure. Labelled columns are markedly reduced in width in layer IVC, but comparatively intact in the upper tier, IV A.



FIGURES 21 AND 22. For description see opposite.

(Facing p. 396)



FIGURES 23 AND 24. For description see opposite.

In all four penetrations the activity recorded from layer IVC was strictly monocular, and in one of these penetrations the positions of six lesions made at the points of transition matched the column boundaries as revealed in subsequent autoradiography (compare figure 15*c*).

Monkey no. 4: morphology

This monkey differed from monkey no. 3 in that the deprived (right) eye, rather than the normal one, was injected. Also the eye was closed at 3 weeks instead of 2, and the closure lasted 7 months rather than 18 (see table 1). Sections of the operculum ipsilateral to the injected and deprived eye are shown in figure 20, plate 9. Part *a* shows a single section which just grazed layer IVC, and *b* shows a slightly deeper section cutting layer V in two places, presumably reflecting some dimpling of the cortex; here IVC has the shape of an 8. These sections form the central part of the reconstruction shown in figure 20*c*. Cutouts of the two sets of columns on this side showed a ratio of areas, normal to deprived, of 1.97:1 (table 3). On the contralateral side this ratio was 1.60:1, suggesting, as in monkey no. 3, that the side ipsilateral to the closed eye was the more severely affected.

The calcarine cortex of the two hemispheres is shown in figure 21, plate 10, contralaterally (A) and ipsilaterally (B); again there is a suggestion that in the ipsilateral hemisphere the labelled columns are narrower than in the contralateral. In addition one can see that the deep part of layer IVC (IVC β) is labelled much more heavily than the superficial. This difference is seen in normal monkeys, but seems more pronounced here, while it might be taken to mean that the IVC α component is more susceptible than IVC β to deprivation effects, the results in monkey no. 3 (see figure 16) suggest, if anything, the very reverse. In the geniculate, furthermore, there was no indication that the magnocellular layers, which correspond to IVC α , were more atrophic than the parvocellular. This is in agreement with the findings of Headon & Powell (1973).

In figure 21*a*, plate 10, a long continuous expanse of layer IV label can be seen over the anterior stem of the calcarine fissure in the region known to represent the part of the visual field temporal periphery that is visible only to one eye (temporal crescent). This label is at least as heavy as in any of the shrunken deprived-eye columns elsewhere on the same slide, and occupies as extensive an area of cortex as it does in the normal monkey. It thus seems that the temporal-crescent representation is little affected by the deprivation procedure. This again supports the suggestion that the effects of monocular deprivation depend on competition between the two eyes rather than simple disuse.

DESCRIPTION OF PLATE 11

FIGURE 23. Normal newborn monkey (no. 9). Autoradiographs of lateral geniculate bodies. The left eye was injected at 1 day of age and the brain examined at 1 week. Upper part, light field, lower, dark field. The label in the layers corresponding to the right, non-injected eye is denser than the background but is in fibres rather than terminals. Several layers other than the six classical ones can be identified; these are indicated in figure 24.

FIGURE 24. Monkey no. 9; same as light-field part of figure 23. Nine regions of input have been identified. In addition to the two classical magnocellular layers, 1 and 2, and the four parvocellular (dorsal) layers, 3, 4, 5, and 6, one can see two thin leaflets *a* and *c*, both contralaterally supplied, the one dorsal to 1 and the other ventral to it; a thin leaflet *d*, sandwiched between the dorsal four and the ventral two classical layers, and probably receiving input from both eyes; and finally a clump of label *b* (ipsilaterally supplied) between *a* and 1, which shows up as a labelled region on the left, and a label-free space on the right.

In this monkey the reduced-silver sections showed no banding, perhaps because the animal was too young. (The method has so far been successful only in animals a year or more old.) No geniculate lesions were made, and consequently no Nauta preparations were available.

Monkey no. 5 (201): Morphology

This animal is included as a second example of monocular closure with deprived eye injected. The right eye was closed at 2 days and opened at 7 weeks, and the animal lived up to an age of 7 months. A more complete description of this monkey will be given as part of a separate paper on duration of the sensitive period and extent of recovery. The opercular autoradiographs were unsatisfactory, showing almost no label, probably because of uneven distribution of the injected material in the eye. A part of the calcarine cortex was labelled, however, and is shown in transverse section in figure 22, plate 10. We include this monkey here because it forms an almost exact complement to monkey no. 3 (figure 16), with the deprived eye injected instead of the normal. Again, as in monkey no. 4, layer IV C α seems more severely affected than IV C β , in apparent contradiction to what was seen in monkey no. 3.

TABLE 4. CELL DENSITY AND SIZE, MONKEY NO. 3, LAYER IV C β , R.H.†

column type	density (cells/ 2500 μm^2)	mean area (μm^2)	(s.d.)	significance (Welch test)
normal	31	48	8.9	N.S.
deprived	30	48	11.1	
normal	33	50	11.8	p < 0.05
deprived	23	41	10.7	
normal	22	54	12.9	N.S.
deprived	37	54	14.6	
normal	29	50	9.6	N.S.
deprived	26	49	8.4	
total:	(cells/ 10000 μm^2)			
normal	115	50		N.S.
deprived	116	49		

† 4 pairs of samples from normal and deprived columns. Each consists of all the neurones in a 2500 μm^2 square in the middle of the column and the middle of the layer.

Gross anatomy and Nissl studies

In monkeys nos. 1-4, there was no obvious change in the extent or overall shape of the striate cortex. No measurements were made of the total area of striate cortex, but the occipital lobes were not grossly shrunk as would be expected if half of the columns had been reduced to a fraction of their normal size; the extent of striate cortex in Nissl-stained sections, moreover, appeared quite normal. This strongly suggests that the shrinkage of one set of columns was compensated for by an expansion of the other set, supporting the conclusion already reached from measurements of the repeat distance. For the same reason it is unlikely that one set simply failed to grow following the eye closure. Indeed, if the differences in column width in monkey no. 3 had been due to a failure of one set to grow, the striate cortex of a 2 week old monkey would have been about one-third its adult size. Far from this, comparisons between newborn and adult show that the newborn brain is closer to 80% of the adult size.

In marked contrast to the lateral geniculates, the Nissl-stained cortex in all of the experimental monkeys appeared normal. In particular, layer IV C gave no hint of any fluctuations in thickness, cell size or cell density, to parallel the changes seen in the autoradiography or degeneration studies. Measurements of cell density and cell size were made in monkey no. 3 to learn whether any minor variations, too subtle to be seen by mere visual inspection under the microscope, might be present. In an autoradiographic section counterstained for Nissl substance, squares were selected in the middle of four normal-eye columns, midway between the borders, and these were compared with squares similarly centred in the neighbouring deprived-eye columns. Each square measured $50\ \mu\text{m} \times 50\ \mu\text{m}$. The locations of column boundaries were determined directly from the autoradiography by examining the same slide under dark-field illumination. Table 4 shows the results of these measurements: no significant differences were seen in cell density or cell size.

PART III. NEWBORN MONKEYS

An interpretation of the findings just described depends heavily on a knowledge of the state of the ocular dominance columns at the time an eye was closed or removed. Some preliminary studies were therefore made on three very young monkeys. The first of these (no. 9) was studied anatomically following eye injection; the second and third were recorded from, the second (no. 10) at 8 days and the third (no. 4) at 22 days.

Monkey no. 9: autoradiography

This monkey was injected in the right eye with 2.0 mCi of tritiated fucose the day after it was born. Though we normally allow 14 days for transport, the animal died of a respiratory infection at 6 days and was perfused probably less than an hour after death.

The geniculates seemed to be fully developed by adult standards. The layers corresponding to the injected eye were heavily labelled, as shown in figure 23, plate 11. On each side the three layers corresponding to the uninjected eye showed some label in excess of background, perhaps somewhat more than was seen in monkeys nos. 3 and 4. Comparisons are difficult, however, given the large amount of label injected relative to the size of the eye or the monkey's weight, the use of fucose alone instead of a fucose-proline mixture, the differences in the time allowed for transport, and a number of other variables that could not be completely controlled.

In addition to the six classical layers, figure 23 shows four subsidiary groups of terminations. These are labelled in figure 24, plate 11. From ventral to dorsal they consist of: (1) a thin layer *a* ventral to layer 1, contralaterally supplied, and separated from most of 1 by a thin label-free gap. (2) A clump of label *b* near the hilum, supplied ipsilaterally and sandwiched between *a* and layer 1. This is seen as a small aggregation of label on the left, and its position is marked by a space on the right. (3) A thin leaflet *c* just dorsal to layer 1, contralaterally innervated, and, like, *a*, separated from layer 1 by a label free gap. (4) A thin leaflet *d* sandwiched between layers 2 and 3, contralaterally innervated so that it stands out clearly between these two, especially in dark-field illumination (figure 23, lower right). This layer is probably also ipsilaterally innervated as shown in light field (see also figure 9). *c* and *d* appear to be joined in some sections by bands of label that pass through layer 2. Layers *a*, *b* and *d* are also shown in figure 9. *a* and *b* probably correspond to the single lamina 'S', described by Campos-Ortega & Hayhow (1970), and thought by them to receive only ipsilateral innervation.

The findings in the striate cortex came as a surprise. At first glance no columns were evident at all. Sections cut in the parasagittal plane through the calcarine fissure contralateral to the injected eye showed almost continuous moderately dense label in layer IV C. This is shown in figure 25*a*, plate 12. The minor fluctuations in density of layer IV label were hard to evaluate in these sections and we were tempted to dismiss them until we examined tangential sections through the dome of the mushroom of the calcarine fissure on the ipsilateral side (figure 25*b*). Though the parallel bands in the central oval region through IV C are faint their regularity is very clear, with a repeat distance of about 700 μm , or 20 % less than our value for the normal adult. Even in the regions of minimum label the density is considerably higher than outside IV C. It is difficult to compare the sides ipsilateral and contralateral to the injected eye because of differences in the planes of section, but our impression is that the fluctuations in density were more marked ipsilaterally.

There are two possible explanations for this result. The first is that label may have leaked from the path originating in the injected eye to the non-injected path. The geniculates would be the most likely site of spillover. Some leakage of this sort may indeed occur in the normal adult, as is shown in figures 12 and 13 by the above-background levels in the gaps between labelled columns. It may be that any such leakage is more serious in the newborn. The second possibility is that the columns are indeed not fully formed at birth, the full extent of layer IV being occupied by terminals from the two eyes, with only minor but regular variations in density representing the precursors of the columns.

Monkeys nos. 10 and 4: physiology

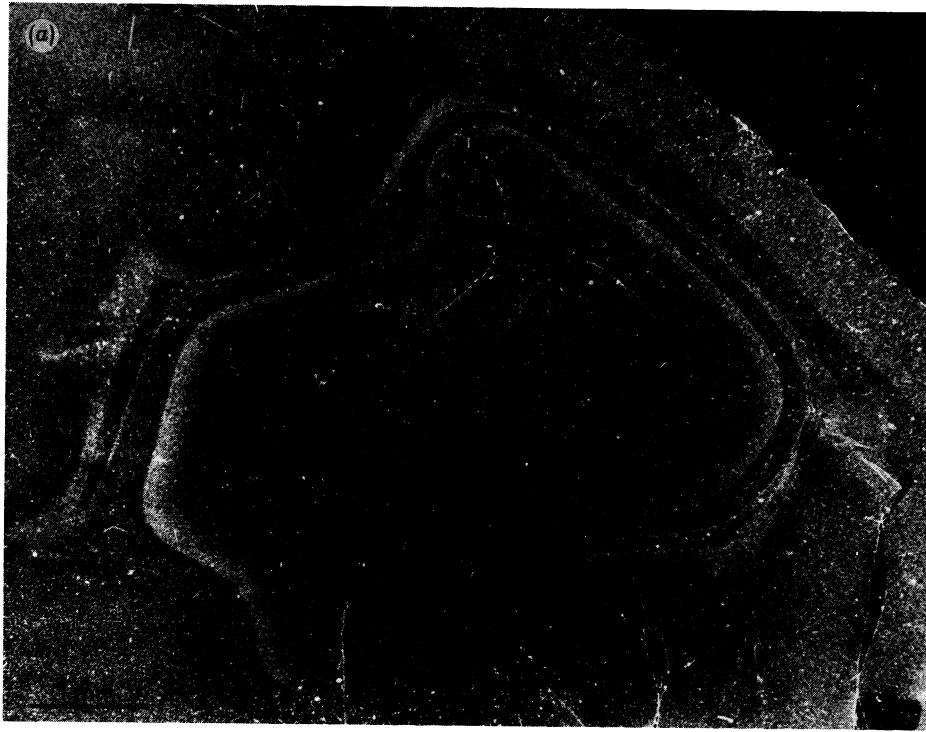

One obvious method for resolving this impasse was to record from a newborn monkey. No. 9, unfortunately, died before recordings could be made. No. 10 was not injected, but was recorded from at 8 days of age, having been in a normally lit nursery up to that time.

Four penetrations were made in monkey no. 10, in area 17 of the left hemisphere. They were made very obliquely so as to explore as great a span of layer IV C as possible. The reconstruc-

DESCRIPTION OF PLATE 12

FIGURE 25. Newborn monkey, no. 9, Autoradiographs in dark field. (a) Transverse section through calcarine fissure and operculum on the right side, contralateral to the injected eye. Label is virtually continuous, both in the fissure and over the convexity, though there is some suggestion of fluctuations in density over the dorsal calcarine stem. (The part of this stem furthest to the left is probably the temporal crescent representation, where one expects continuous label; compare figure 21*a*.) Anterior is up and to the left. (b) Tangential section through operculum of left occipital lobe (ipsilateral to the injected eye). Section passes deep to the outer convexity, and cuts the buried mushroom-like calcarine convexity, grazing layer IV C which appears as an oval near the centre. Throughout this area levels of label are well above background, but there is nevertheless a definite regular banding with a periodicity of about 0.7 mm. 1–2 mm outside of the oval is a ring of label formed by the optic radiations. Still further out is a continuous double ring of label in layers IV C α and β of the outer exposed convexity.

FIGURE 26. Reconstructions of four penetrations made in striate cortex of an 8-day-old monkey (left hemisphere). The object was to explore as long an extent of layer IV C as possible, determining how much binocular mixing was present. Circles indicate points at which electrolytic lesions were made. The lower diagram indicates, on the left, the ocular dominance of the multiunit activity in layer IV C. The right hand portion, with smaller dots, indicates ocular dominance of the cells in the upper layers, in the early parts of the penetrations. The points are pooled from all four penetrations, preserving the cortical position of each recording site. In the region explored, obviously the contralateral (right) eye dominated in the portions to the left and right and the ipsilateral eye dominated in the middle. For the left hand region the input was almost exclusively contralateral; in the middle region, however, there was considerable mixing of inputs from the two eyes. In adult monkeys virtually no mixing is found in layer IV C.



OD.
GROUP



1 mm

LAYER IV c

II, III, & IV a,b

FIGURES 25 AND 26. For description see opposite.

(Facing p. 400)

tion of these penetrations is shown in figure 26, plate 12, with the ocular dominance of the cells indicated below. Points to the left of the gap in the diagram indicate units or unit clusters in layer IVC. The smaller dots, to the right of the gap, indicate cells in the upper layers. Our main concern was of course to learn whether single cells or local groups of cells in IVC were fed from one eye or from both.

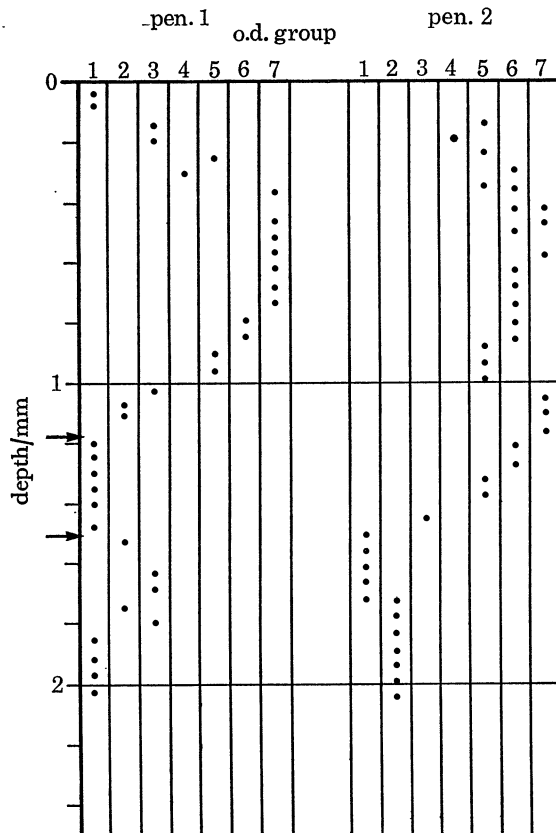


FIGURE 27. Ocular dominance in two penetrations made at 45° through right striate cortex of a normal 3-week-old monkey (no. 4, first recording, compare figure 19). Penetration 1 passed through layer IVC in the region indicated by the arrows; this activity was strictly monocular. There are clear regular fluctuations in ocular dominance, just as is found in adult monkeys.

The first penetration was normal by adult standards: in the layers above IVC most cells had sharp orientation specificity and most were driven from both eyes, one or other being preferred. The contralateral eye dominated at first, then came a span of about 1 mm in which the ipsilateral eye dominated, and finally, in IVC, all cells had unoriented fields and were activated from the contralateral eye only. In the other three penetrations, binocular cells similarly prevailed in the upper layers, but in IVC a variable amount of binocular input was also found. Thus in penetrations 2 and 3 the ipsilateral eye dominated but the contralateral contributed weakly or moderately throughout the traverse through IVC, while in penetration 4 the two eyes were almost equal. These observations refer mostly to the unresolved multiunit activity, since single units are hard to resolve in IVC. Nevertheless, there were in layer IVC several clear examples of binocularly driven cells with no preferred orientation. In this monkey, then, layer IVC showed the usual variation in eye emphasis, but much more binocular mixing than we have ever found in juvenile or adult monkeys.

A recording was also made in monkey no. 4 at 3 weeks of age, up to which time both eyes had been normally exposed. (After the recording the monkey was resurrected and the right eye was sutured closed.) In this animal the results were very similar to those previously obtained in the adult, and are illustrated in figure 27. In both penetrations (each at about 45°) binocularly driven cells were present in abundance above and below layer IVC, with the normal swings in dominance from eye to eye. The short passage through layer IVC in penetration 1 (between arrows) showed monocular influence only, but a subsequent experiment in a 3-week-old monkey has indicated a lack of complete segregation in this layer; another at 6 weeks suggests that by then segregation is virtually complete. (These experiments are part of a separate study on the time course of columnar development.)

Thus early in life layer IVC probably contains a mixture of inputs from the two eyes, perhaps at most points along its length; by 3 weeks, on the other hand, segregation seems to be fairly well advanced but probably still not complete.

DISCUSSION

The chief finding of the present study concerns the effects of early eye removal or monocular lid closure on the ocular dominance stripes in layer IVC. Deprivation in the first few weeks of life resulted in a change in the relative sizes of the two sets of stripes, with a shrinkage of stripes receiving input from the deprived eye and a corresponding expansion of those with input from the normal eye.

In discussing the nature of these changes a number of possibilities can be quickly dispensed with. The first of these is the notion that in the shrunken columns the reduction is only apparent: that in the areas invaded by the normal-eye terminals, the terminals from the deprived eye remain but are non-functional. The concept of non-functional synapses in the nervous system is not unheard of, the best established example probably being botulinum poisoning at the nerve-muscle junction. In the present experiments, given the variety of techniques we have used to demonstrate the abnormalities, one would have to suppose in this model not only that the synapses were physiologically non-functional, but that the fibres did not degenerate after geniculate lesions in such a way as to show up with Nauta-Fink-Heimer methods, did not transport materials normally, and were not revealed with reduced silver stains. Such an interpretation thus seems most improbable.

Secondly, we must consider the idea that there is not only an abnormal distribution of terminals in layer IV, but also a change in the territory occupied by each entire band, cells and all. This could only happen if the cell packing density deviated markedly from normal, increasing in the shrunken columns and decreasing in the expanded ones, or if cells died in large numbers in one set and proliferated in the other. But a fluctuation in packing density of the magnitude necessary to fit the changes in width that we see can be ruled out by direct counts (table 4), while cell proliferation ceases altogether in the cortex 2 months before term (Rakic 1974), and a cell death sufficient to equalize the cell counts would produce a radical drop in cell numbers which in fact does not occur.

Thirdly, there is a possibility that the brain of the newborn monkey is much smaller than that of the adult, and that the columns in area 17 are present at birth and also correspondingly smaller. The disparity in column size would then arise if the columns connected to the deprived eye simply failed to grow. It appears, however, that in overall size the striate cortex increases

very roughly 20% after birth – it certainly does not double or triple in area as would be required to explain the discrepancies in column width. Consistent with this, the columns in the newborn show a periodicity not very different from that of the adult, to judge from direct anatomical (figure 25*b*) and physiological (figures 26 and 27) observations. Finally, there is the finding that in the deprived animals the columns associated with the open eye are larger than normal, and the combined width of a left eye–right eye pair is unchanged. None of this would be consistent with an explanation based on failure to grow.

With these possibilities out of the way, a discussion of the pathogenesis of the changes due to deprivation hinges strongly on a knowledge of the state of the columns at birth. If one assumes that in the newborn monkey (or within a few days of birth) the geniculocortical fibres have already taken up their final positions in the form of clearly defined parallel IVth-layer stripes, then it is hard to avoid the conclusion that in the final state one set of terminals has extended its territory, possibly by sprouting, while the other set has retracted. If sprouting were involved here it would be of some interest. Although a number of examples of sprouting have been reported, all of them were brought about by a destructive deafferentation of one source of input to a structure. In the present series even eye enucleation amounts to a lesion one synapse away from the site of the changes, and the eye closures involve no direct destruction of any neural tissue. If the changes in layer IV are indeed produced by sprouting and retraction the result is in marked contrast to what is seen in the geniculate or colliculus, for there we have no hint of invasion of terminals from the normal eye into the deprived or deafferented territory. This may simply be a matter of timing with respect to normal developmental events, since it is known that in enucleated cats there is no invasion of afferents into a deprived geniculate layer unless the enucleation is done in the first week after birth (Kalil 1972; Guillery 1972*b*). Even then the invasion is modest and occurs only near the laminar borders; that it occurs at all is probably related to the immaturity of the cat visual system at birth, compared with that of the monkey.

Up to the time when we saw the results of autoradiography in the newborn, described in Part III, we regarded a sprouting of terminals as the strongest contender in explaining the cortical changes. Our previous physiological recordings in young monkeys (Hubel & Wiesel 1974) had actually tended to support the idea that ocular dominance columns were present at birth. By the second day, for example, there was a clear grouping of upper-layer, mostly binocular, cells according to ocular dominance, and in an animal with both eyes closed up to 3 weeks there was an almost complete segregation of eye inputs even in the upper and lower layers, reminiscent of the picture obtained with artificial strabismus. Tangential penetrations were not used in either of these animals, however, so that no clear idea was obtained of the state of affairs in layer IVC.

In the present paper both the physiological recordings and the anatomy in monkeys in the first week or so of life strongly suggest that the sets of terminals associated with the two eyes have arrived at layer IVC but have not yet separated themselves out completely into distinct bands. There is, to be sure, a clear banding visible in the autoradiographs in tangential sections (monkey no. 9, figure 25*b*), but these are produced by mild fluctuations in levels of label, rather than a series of abrupt rises and falls from maximum to minimum and back. The physiology in monkey no. 10 confirmed this mixing of inputs, though there was perhaps more segregation than would have been expected from the autoradiographic picture.

The notion that the columns are not fully formed at birth in this species can at present be

only rather tentative; what is still needed is a set of injections and recordings at various ages in the first 6 weeks. But our results so far receive support from the findings of Rakic (1976*a, b*), in foetal monkeys in which one eye was injected with radioactive label at different times during gestation. At 6 weeks before term label was present in IV C but appeared uniform, with no hint of columns. Three weeks before term there were fluctuations in label density that were only barely discernable on visual inspection of transverse sections, but were clearly confirmed by grain counts. As with our eye-injection results, one must keep in mind the possibility of leakage of label in the geniculate.

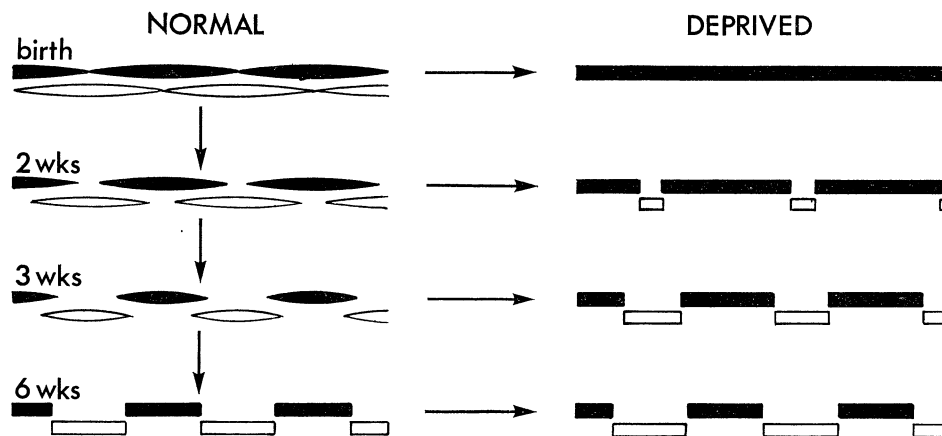


FIGURE 28. Scheme that might explain the effects of eye closures on columns in layer IV C, on the assumption that the segregation of the eyes is not complete until some weeks after birth. The thick dark lines represent the terminations of geniculate afferents in layer IV C corresponding to one eye; the open lines, the terminations from the other eye. In each, the width is intended to represent the presumed density of the terminals. At birth there is some periodic and regular variation in density (figure 25*b*): it is unlikely that the minimum is zero, as the drawing suggests, and in any case the fluctuations are probably different in different parts of the striate cortex. In this scheme we suppose that competition normally occurs between the eyes, with the weaker input at any given point declining and the stronger being fortified. The result is a progressive retraction as the sparse terminals die out entirely. For purposes of the drawing we assume that the retraction process has the time course illustrated and that it takes about 6 weeks; again, the exact time course is far from clear.

If the columns do, as it were, crystallize out only in the few weeks before and after term, the process presumably occurs by a retraction of the two sets of terminals. One may imagine that in any areas occupied by both sets of terminals there is a competitive mechanism in which the weaker set at any point tends to regress. Given such an unstable equilibrium, the normal end result of any initial inequalities would be a complete segregation of terminals. Such a model for the normal development, based on competition, is illustrated schematically in the left half of figure 28. In this figure the terminals dominated by one eye in layer IV C are blackened, and the other set is represented by open areas. (Obviously the two sets should be superimposed, but are shown one under the other for clarity.) The thickness of these representations suggests the relative density of label at each point along IV C. If we suppose that at birth there exist some mild periodic out-of-phase fluctuations (which may be less than portrayed here) the density of the weaker inputs at any point will decline, with consequent production of a series of ever widening gaps until all overlap is eliminated.

On this model for the normal development, the deprivation results in layer IV can be predicted. One has only to assume that lack of use of a set of terminals puts them at a competitive disadvantage which transcends that related to mere numbers, so that at any point along IV C

the terminals from the opposing normal-eye set take over, provided they have not already retracted. This is illustrated in the right half of figure 28. Where no competition is possible, because the other set has already disappeared (or in the case of the temporal crescent representation, where only one set was present from the beginning – see figure 21*a*) the deprived set survives and is apparently intact. The end result of the deprivation thus depends on the amount of overlap that still existed at the time of eye closure or removal.

It should be emphasized that the details of figure 28, such as the ages assigned to the four illustrated stages of development or the amount of fluctuation of label density at birth, should not be taken literally. We do *not* know, for example, that closure of an eye from birth produces a complete takeover by the open eye. The illustration merely provides, at present, the best fit with the results from the few deprivation and control monkeys available (nos. 1–5, and 9 and 10). We are still uncertain of the variation to be expected from one animal to the next, even under experimental conditions that are as similar as possible.

One advantage of the scheme of figure 28 is that it removes some of the mystery connected with the ‘critical period’ – the period of susceptibility to monocular deprivation. At least as far as layer IV is concerned the flexible state would, by this model, involve not some kind of ill-defined vulnerability to insult, or capacity for nerve-terminal proliferation, but merely the period of development from birth to the final consolidation of the columns.

If the idea of a post-natal retraction of inputs is correct, it would be interesting to know whether there are consistent differences in the timing of the process, in different parts of area 17 (for example, foveal *vs.* more peripheral representations) and, in a given hemisphere, between terminals belonging to the ipsilateral and contralateral eyes. As far as laterality is concerned, deprivation effects have consistently been more severe in the hemisphere ipsilateral to the eye that was closed; this has been true both for the shrinkage of cortical columns and the attendant geniculate atrophy (see also Headon & Powell 1973). On the model of figure 28 this would be readily explained if it were found that the fibres from the contralateral eye were slower in retracting than their counterparts from the ipsilateral. We have fragmentary hints that this may indeed be so, since in the layer IVC recordings from monkey no. 10 (figure 26) at 8 days the contralateral eye had already gained exclusive possession of some territory in IVC, whereas the ipsilateral eye had not. On the competition model a closure of the contralateral eye would find ipsilateral terminals available only in the designated ipsilateral territory; a closure of the ipsilateral eye would find terminals from the contralateral eye available to take over everywhere. The autoradiography (figure 25) tended to support this idea, although comparisons were difficult since the planes of section in the two hemispheres were different.

The model of course says nothing about changes in connections beyond layer IVC. That such changes almost certainly occur is shown by the scarcity in deprived animals of cells in layers outside IV that can be influenced from the closed eye, a scarcity more severe than would be expected from the extent to which deprived stripes in IVC are spared, and the relative normality of responses within those stripes. (We were, in fact, surprised when we first recorded from layer IVC to find any significant number of cells responsive to the deprived eye.) Also it is clear that monocular deprivation can produce changes in the ocular dominance of cells outside layer IV when closures are done well beyond 6 weeks – effects are seen as late as 4 months and possibly even later, if an eye is closed for a long enough time. We have some indication, from reduced silver stains, that such late deprivation leaves the layer IV band widths unchanged. Thus eye-dominance changes in higher order cells may have to be explained in terms of competition

between different groups of afferents for territory on a single postsynaptic cell, as has been proposed previously (Wiesel & Hubel 1965). Indeed, an important reason for doing the present experiments was a curiosity to learn what would happen in layer IVC, where competition between eyes on a single-cell level seemed impossible. This is in contrast to the situation in the cat, in which the physiology suggests that there is a direct convergence of geniculate afferents from the two eyes on cortical cells. It now appears that the mechanisms for the layer-IV changes in the monkey could also involve competition, since before the columns are fully formed terminals from the two eyes may likewise converge on single cells in that layer. The presence of a few resolvable binocular cells in layer IVC of monkey no. 10 (at 8 days) tends to support this, although we admittedly have no guarantee that the particular cells we recorded received direct input from the geniculate. The question would have to be resolved by intracellular or morphological (EM) techniques. In any case, it is probably easier to imagine competition between afferents for territory on a single cell than a competition between entire columns or large groups of afferents.

Since the notion of competition between eyes is now a dominant one in visual deprivation, and a recurring theme in the present paper, it may be useful to review some of the evidence in its favour. It was originally suggested to account for the surprising finding that binocular deprivation in cats produced defects in cortical cell responses that were far milder than predicted from monocular closures (Wiesel & Hubel 1965). This seemed to rule out simple disuse as a mechanism for the unresponsiveness of cells when one eye was deprived. In 1970 Guillery & Stelzner observed that in the geniculate of monocularly deprived cats the part of layer A representing the temporal crescent did not show the same defect in cell growth as the rest of this layer: a possible explanation advanced to explain this was competition between the two eyes, with a sparing of the part of the geniculate in which there could be no competition. Since convergence of input from the two eyes occurs first (for all practical purposes) in the cortex, it was suggested that the cell shrinkage in the geniculate might reflect a failure of axon terminals to compete effectively for synaptic surface of cortical cells. Subsequent experiments have strengthened this idea: (1) In cats deprived of vision in one eye, focal retinal lesions in the open eye produced a protection from deprivation effects, of just those geniculate cells whose competition had been removed (Guillery 1972*a*). (2) Behavioural tests after monocular deprivation showed relatively normal responses to visual cues in the temporal crescent of the deprived eye (Sherman 1973). (3) Sherman, Guillery, Kaas & Sanderson (1974), finally, showed that focal retinal lesions in the eye that remained open protected the closed eye from defects in behavioural and cortical-cell responses in the corresponding part of the visual field.

To this accumulated evidence the present paper has added the anatomical observation that the temporal-crescent input to the monkey cortex is largely spared on the side opposite to the closed eye, compared to the severe effects on cortical columns in the binocular part of area 17. One would expect also to see a sparing of the corresponding geniculate cells, as is found in the cat, but for this problem parasagittal sections would probably be necessary. In a study of the geniculate in monocularly deprived monkeys, von Noorden, Middleditch & Crawford (1975) saw no sparing in the monocular segment representation.

It is worth noting, in this context, that in the foetal eye-injection experiments of Rakic (1976*a, b*) the optic afferents both to the geniculates and to the superior colliculi occupied their entire targets for an extended period between their first arrival and their eventual segregation into layers (geniculates) or clumps (colliculi). In both targets segregation occurred during the

middle period of gestation and was apparently complete by birth. A similar process, then, may well take place in geniculate, colliculus and cortex, though in the cortex it seems to occur later, and to be still incomplete at birth. This would suggest that the apparent reluctance of optic terminals in geniculate and tectum to extend their territory in monocular deprivation is a reflection of the complete segregation of the terminals at birth: the deprivation simply comes too late to produce an effect.

Though direct proof is still lacking, there are strong indications that the formation of ocular dominance columns does not require visual experience, even though some of the formation takes place postnatally and can be rendered abnormal by binocular closure. At present there are two kinds of evidence for this: (1) the autoradiographs at and before birth, i.e. the bands seen on tangential sections (figure 26*b*) or the fluctuations in grain counts 21 days before term (Rakic 1976*b*); and (2) physiological recordings at 4 weeks in monkeys with both eyes closed at birth (Wiesel & Hubel 1974), where layer IV was not examined carefully, but extreme eye segregation was present in the layers outside IV, and therefore, *a fortiori*, in IV. We have examined one macaque dark raised to an age of 6 weeks, and found the responses in layer IVC to be strictly monocular. What is still needed is autoradiography after eye injection in a monkey dark reared, or with both eyes sutured, for the first six weeks or more.

The model involving mutual competition to explain the normal process of post-natal IVth layer segregation presupposes some initial inequality that starts the process. It would be most interesting to know what causes this, and what forces lead to a pattern of parallel lines roughly 0.4 mm apart. If the model is correct it must explain the obliteration of the deprived columns at irregular intervals along the bands, seen in cases of early eye closure (see figure 15), and hinted at in the eye-removal reconstructions (figure 6). Perhaps the process begins at multiple foci along the future bands and spreads in two directions forming line segments which then join similar segments, while simultaneously widening. (On a sprouting model one is tempted to conclude that the obliteration of columns here and there reflects an instability in the columns when they shrink beyond some limiting width.)

An intriguing problem arises from a consideration of the topographic representation of the visual field upon layer IVC (Hubel, Wiesel & LeVay 1974). This topography is detailed enough so that in crossing a single eye-dominance column one can observe a precisely corresponding displacement of receptive fields through the visual field. A displacement of equal magnitude, but in the visual field as seen by the other eye, takes place when the next column is crossed. The representations seem to be interlaced, so that on crossing a boundary between columns the receptive fields in the second eye jump back to about the midpoint of the territory just traversed in the first eye. All of this means that the magnification (mm/deg) across a column must be one-half that along its length. What happens, then, when two neighbouring columns are distorted, one compressed and the other expanded? How do the magnifications change during development? Answers to these questions may lead to a deeper understanding of the developmental mechanisms by which topographic representations arise.

Finally, one may ask again whether there is any benefit to the animal in having a critical period of postnatal flexibility. Does a virtual doubling of the IVth layer territory devoted to one of the eyes in any way improve the capabilities of that eye? Until behavioural tests can be made this question must be left open, but one would hardly expect to find an improvement in acuity, which is presumably limited by such things as the optics of the eye, the inter-receptor spacing, and the number of bipolar and ganglion cells. If an eye is lost early in life a number of cortical

cells are clearly kept in use rather than being allowed to lie fallow, but how this helps the animal, if it does at all, is a complete mystery.

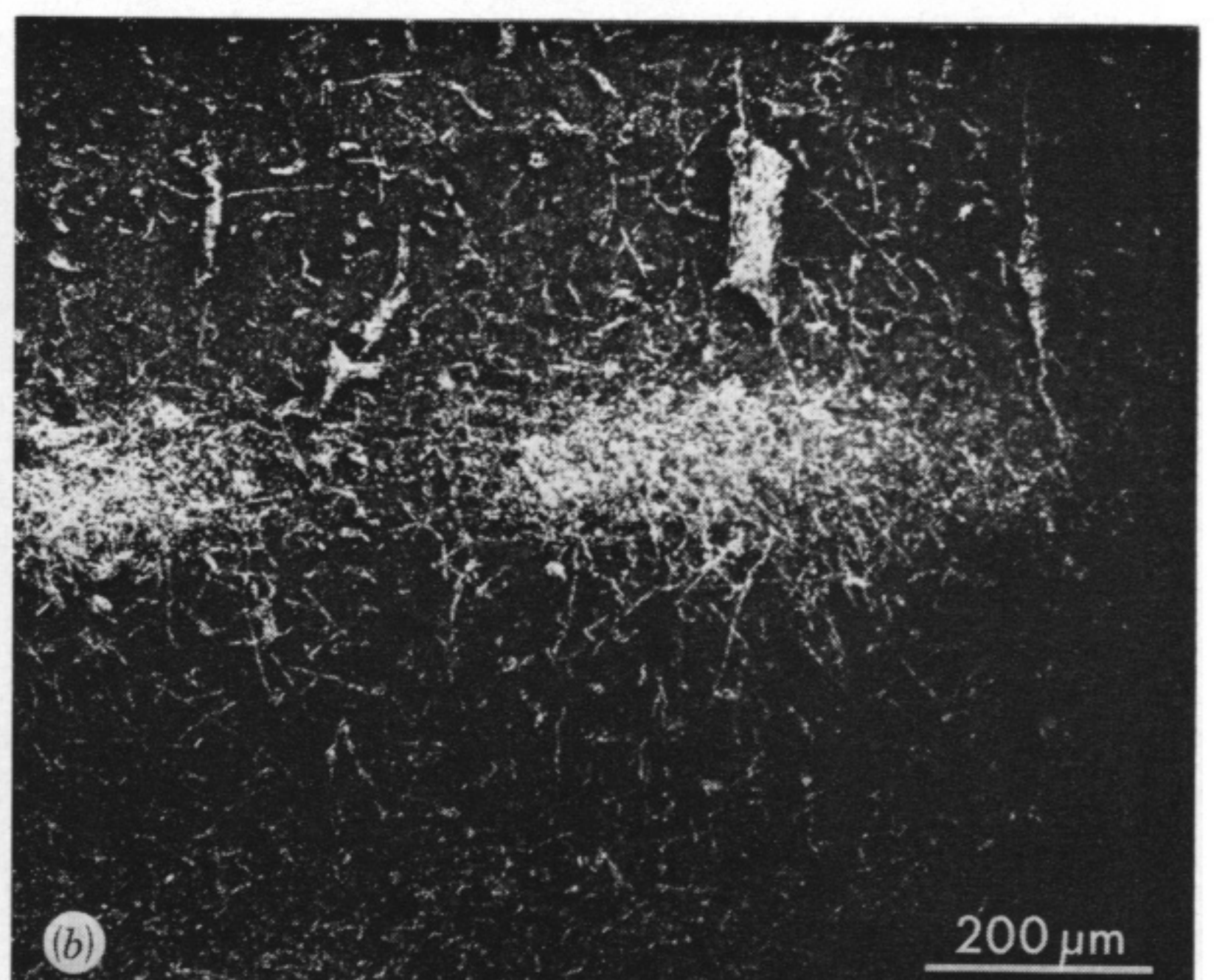
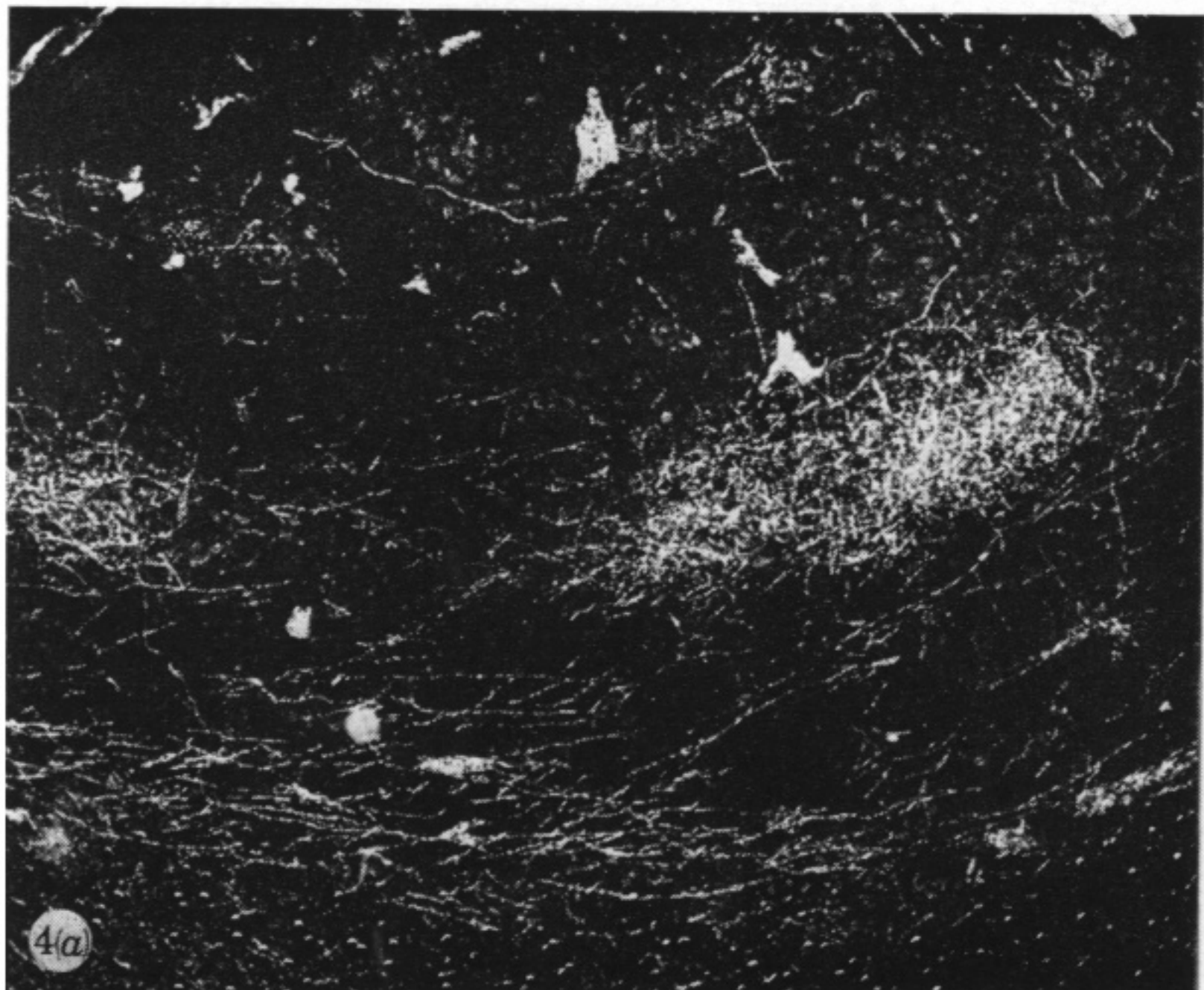
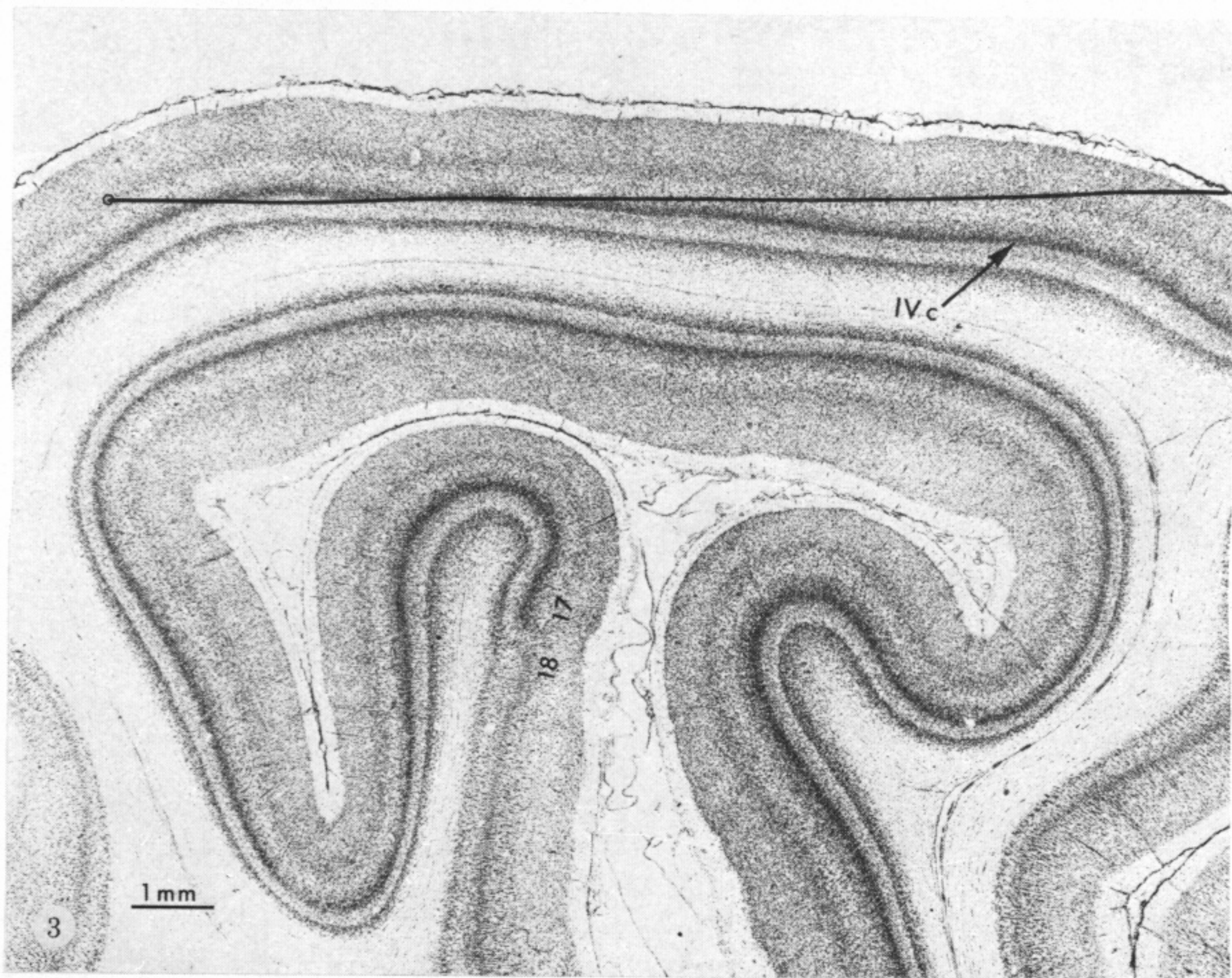
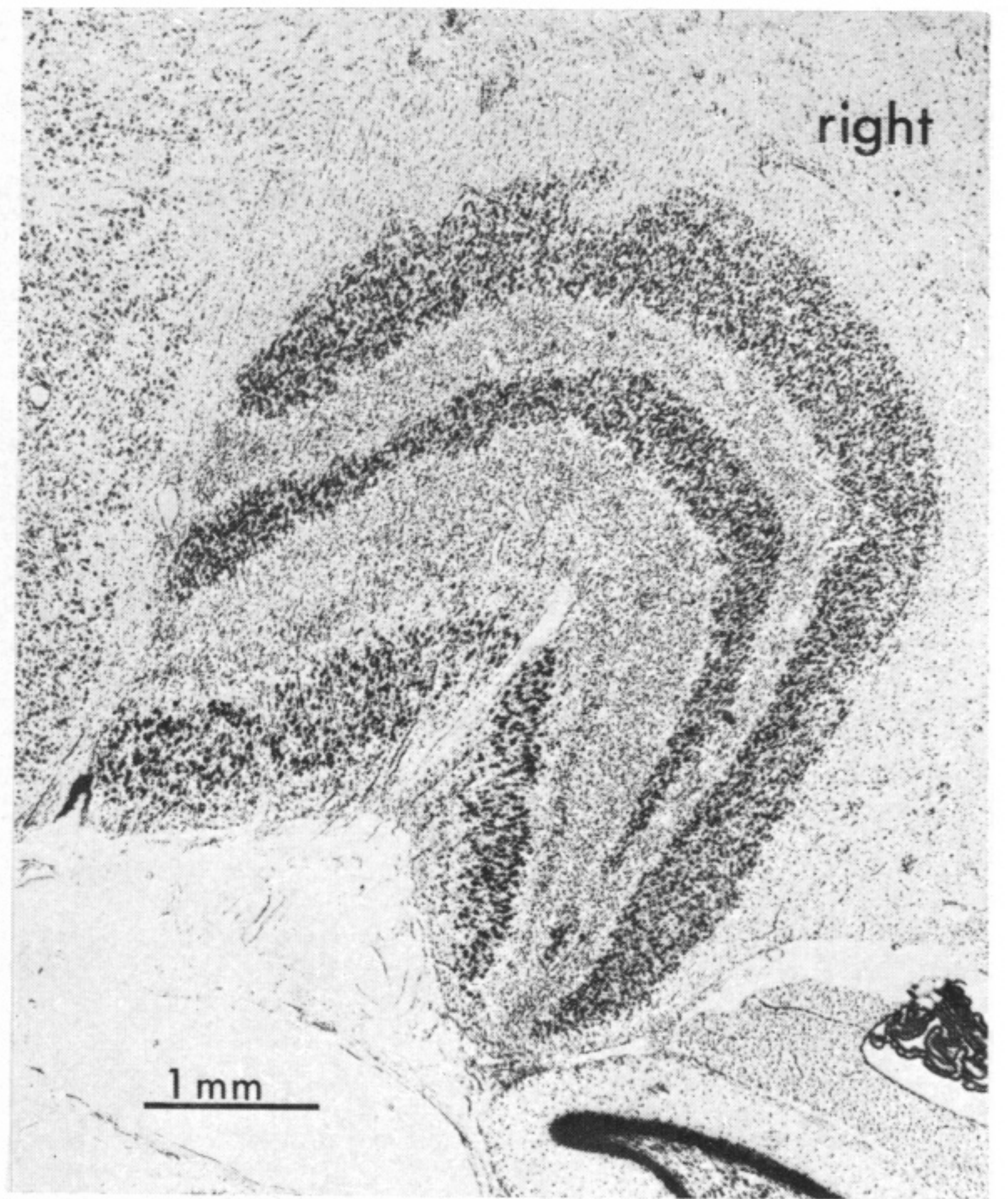
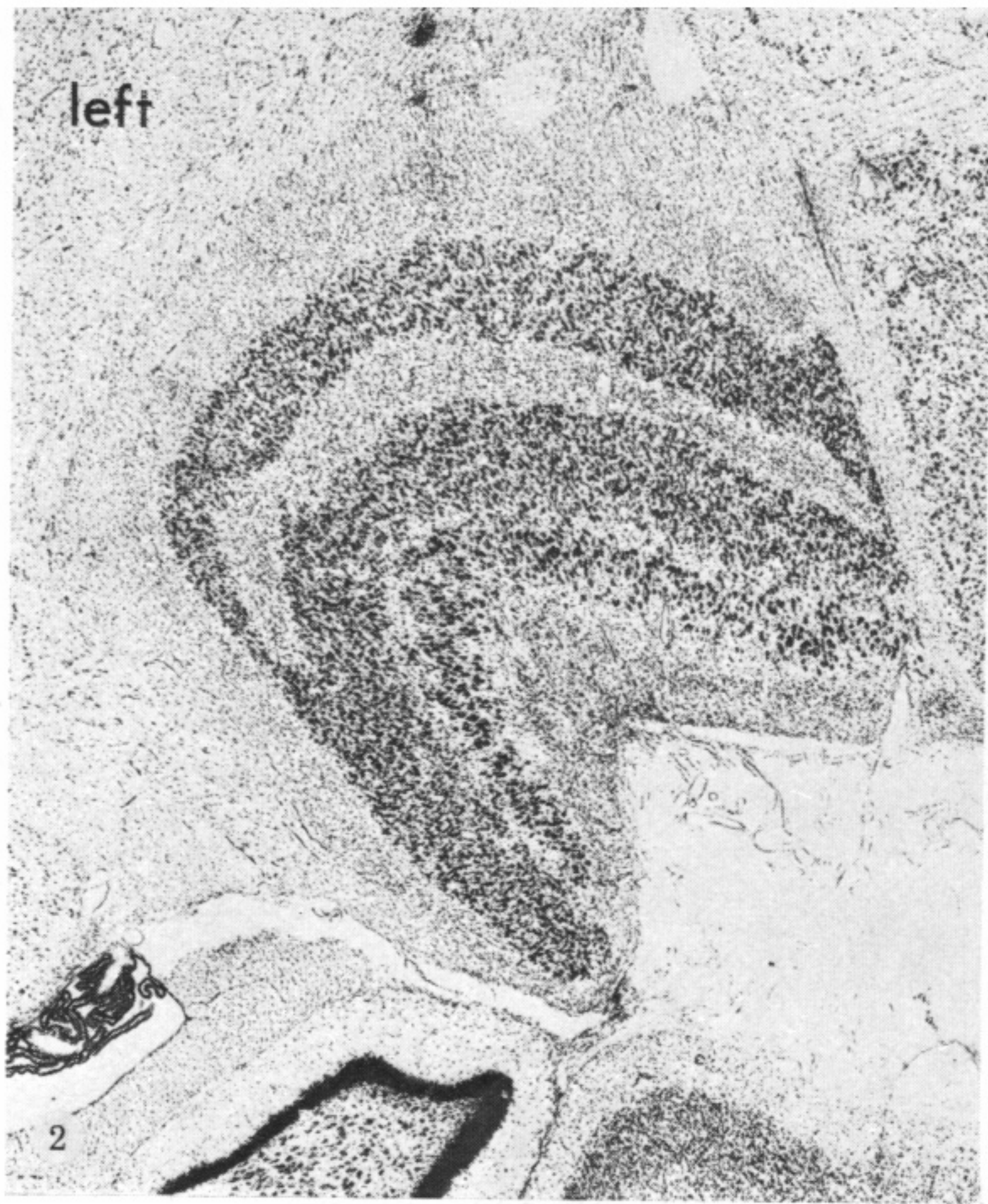
We wish to thank Claire Wang, Gail Grogan and Sharon Mates for histological assistance, and Carolyn Scott for help with photography.

Supported by National Institutes of Health Grants EY00605 and EY00606, The Esther A. and Joseph Klingenstein Foundation, Inc. and The Rowland Foundation, Inc.

REFERENCES (Hubel, Weisel & LeVay)

- Baker, F. H., Grigg, P. & von Noorden, G. K. 1974 Effects of visual deprivation and strabismus on the response of neurons in the visual cortex of the monkey, including studies on the striate and prestriate cortex in the normal animal. *Brain Res.* **66**, 185–208.
- Campos-Ortega, J. A. & Hayhow, W. R. 1970 A new lamination pattern in the lateral geniculate nucleus of primates. *Brain Res.* **20**, 335–339.
- Guillery, R. W. 1972*a* Binocular competition in the control of geniculate cell growth. *J. Comp. Neur.* **144**, 117–130.
- Guillery, R. W. 1972*b* Experiments to determine whether retinogeniculate axons can form translaminal collateral sprouts in the dorsal lateral geniculate nucleus of the cat. *J. Comp. Neur.* **146**, 407–420.
- Guillery, R. W. & Stelzner, D. J. 1970 The differential effects of unilateral lid closure upon the monocular and binocular segments of the dorsal lateral geniculate nucleus in the cat. *J. Comp. Neur.* **139**, 413–422.
- Headon, M. P. & Powell, T. P. S. 1973 Cellular changes in the lateral geniculate nucleus of infant monkeys after suture of the eyelids. *J. Anat. (Lond.)* **116**, 135–145.
- Hubel, D. H., LeVay, S. & Wiesel, T. N. 1975 Mode of termination of retinotectal fibers in macaque monkey: an autoradiographic study. *Brain Res.* **96**, 25–40.
- Hubel, D. H. & Wiesel, T. N. 1968 Receptive fields and functional architecture of monkey striate cortex. *J. Physiol., Lond.* **195**, 215–243.
- Hubel, D. H. & Wiesel, T. N. 1972 Laminar and columnar distribution of geniculo-cortical fibers in the macaque monkey. *J. Comp. Neur.* **146**, 421–450.
- Hubel, D. H., Wiesel, T. N. & LeVay, S. 1974 Visual field representation in layer IVC of monkey striate cortex. *Soc. Neurosci., 4th Annual Meeting (Abstracts)* 264.
- Kalil, R. E. 1972 Formation of new retino-geniculate connections in kittens after removal of one eye. *Anat. Rec.* **172**, 339–340.
- LeVay, S., Hubel, D. H. & Wiesel, T. N. 1975 The pattern of ocular dominance columns in macaque visual cortex revealed by a reduced silver stain. *J. Comp. Neur.* **159**, 559–576.
- Lund, J. S. & Boothe, R. G. 1975 Interlaminar connections and pyramidal neuron organisation in the visual cortex, area 17, of the macaque monkey. *J. Comp. Neur.* **159**, 305–334.
- Matthews, M. R., Cowan, W. M. & Powell, T. P. S. 1960 Transneuronal cell degeneration in the lateral geniculate nucleus of the macaque monkey. *J. Anat.* **94**, 145–169.
- Minkowski, M. 1920 Über den Verlauf, die Endigung und die zentrale Repräsentation von gekreuzten und ungekreuzten Sehnervenfasern bei einigen Säugetieren und bei Menschen. *Schweiz. Arch. Neur. u. Psychiat.* **6**, 201–257.
- Rakic, P. 1974 Neurons in rhesus monkey visual cortex: systematic relation between time of origin and eventual disposition. *Science, N.Y.* **183**, 425–427.
- Rakic, P. 1976*a* Prenatal genesis of connections subserving ocular dominance in the rhesus monkey. *Nature, Lond.* (in the press).
- Rakic, P. 1976*b* Prenatal development of the visual system in the rhesus monkey. *Phil. Trans. R. Soc. Lond. B* **278**, 245–260 (this volume).
- Sherman, S. M. 1973 Visual field defects in monocularly and binocularly deprived cats. *Brain Res.* **49**, 25–45.
- Sherman, S. M., Guillery, R. W., Kaas, J. H. & Sanderson, K. R. 1974 Behavioral, electrophysiological and morphological studies of binocular competition in the development of the geniculo-cortical pathways of cats. *J. Comp. Neur.* **158**, 1–18.
- Spatz, W. B., Tigges, J. & Tigges, M. 1970 Subcortical projections, cortical associations and some intrinsic interlaminar connections of the striate cortex in the squirrel monkey (*Saimiri*). *J. Comp. Neur.* **140**, 155–174.
- von Noorden, G. K., Middleditch, P. R. & Crawford, M. L. J. 1975 Disuse or abnormal binocular interaction in the etiology of amblyopia. *Proc. A.R.V.O.* p. 79.
- Wiesel, T. N. & Hubel, D. H. 1963 Single-cell responses in striate cortex of kittens deprived of vision in one eye. *J. Neurophysiol.* **26**, 1003–1017.

- Wiesel, T. N. & Hubel, D. H. 1965 Comparison of the effects of unilateral and bilateral eye closure on cortical unit responses in kittens. *J. Neurophysiol.* **28**, 1029-1040.
- Wiesel, T. N. & Hubel, D. H. 1971 Long-term changes in the cortex after visual deprivation. *Proceedings of the International Union of Physiological Sciences*.
- Wiesel, T. N. & Hubel, D. H. 1974 Ordered arrangement of orientation columns in monkeys lacking visual experience. *J. Comp. Neur.* **158**, 307-318.
- Wiesel, T. N., Hubel, D. H. & Lam, D. N. K. 1974 Autoradiographic demonstration of ocular-dominance columns in the monkey striate cortex by means of transneuronal transport. *Brain Res.* **79**, 273-279.
- Wiitanen, J. T. 1969 Selective silver impregnation of degenerating axons and axon terminals in the central nervous system of the monkey (*Macaca mulatta*). *Brain Res.* **14**, 546-548.



FIGURES 2-4. For description see opposite.

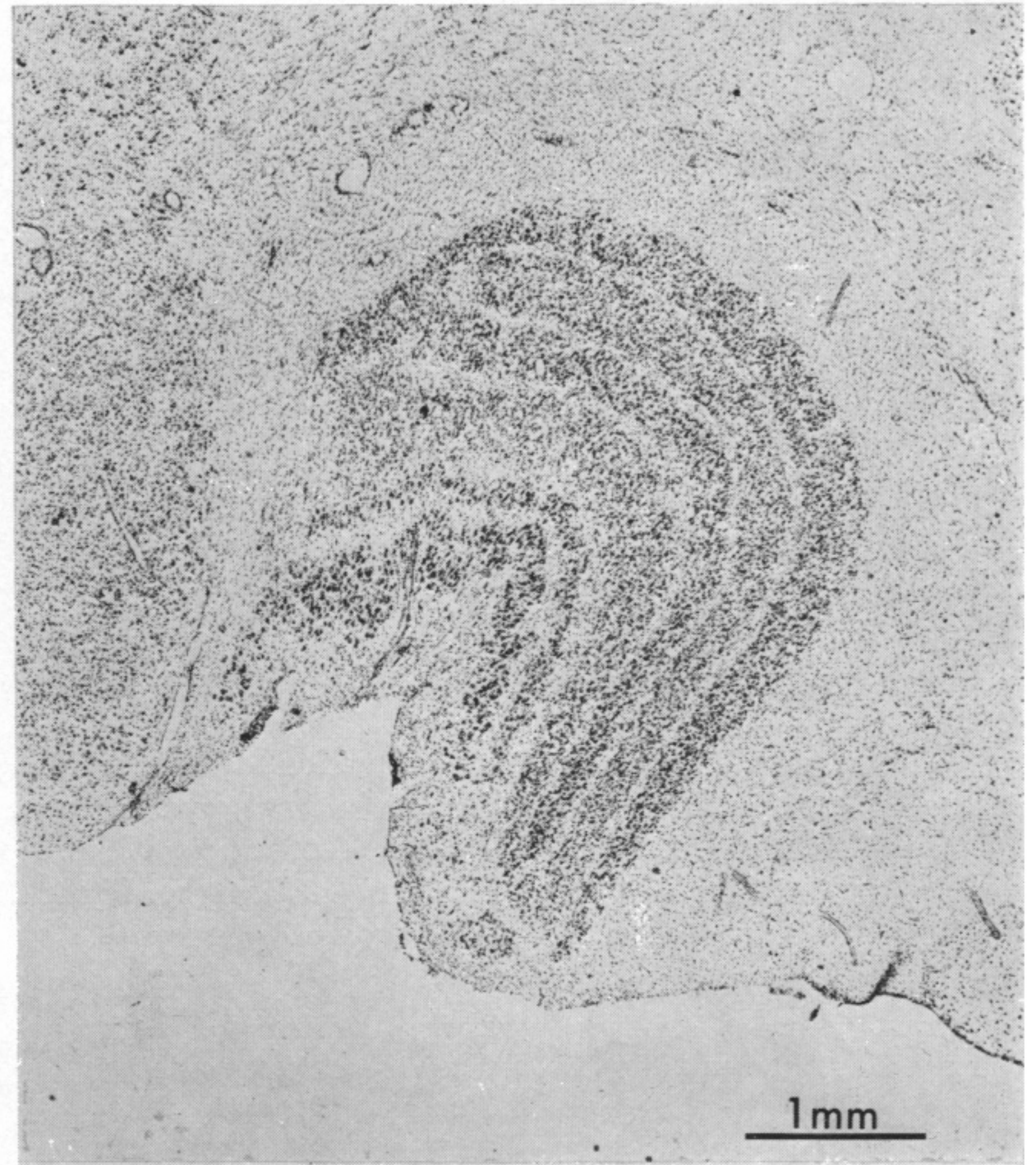
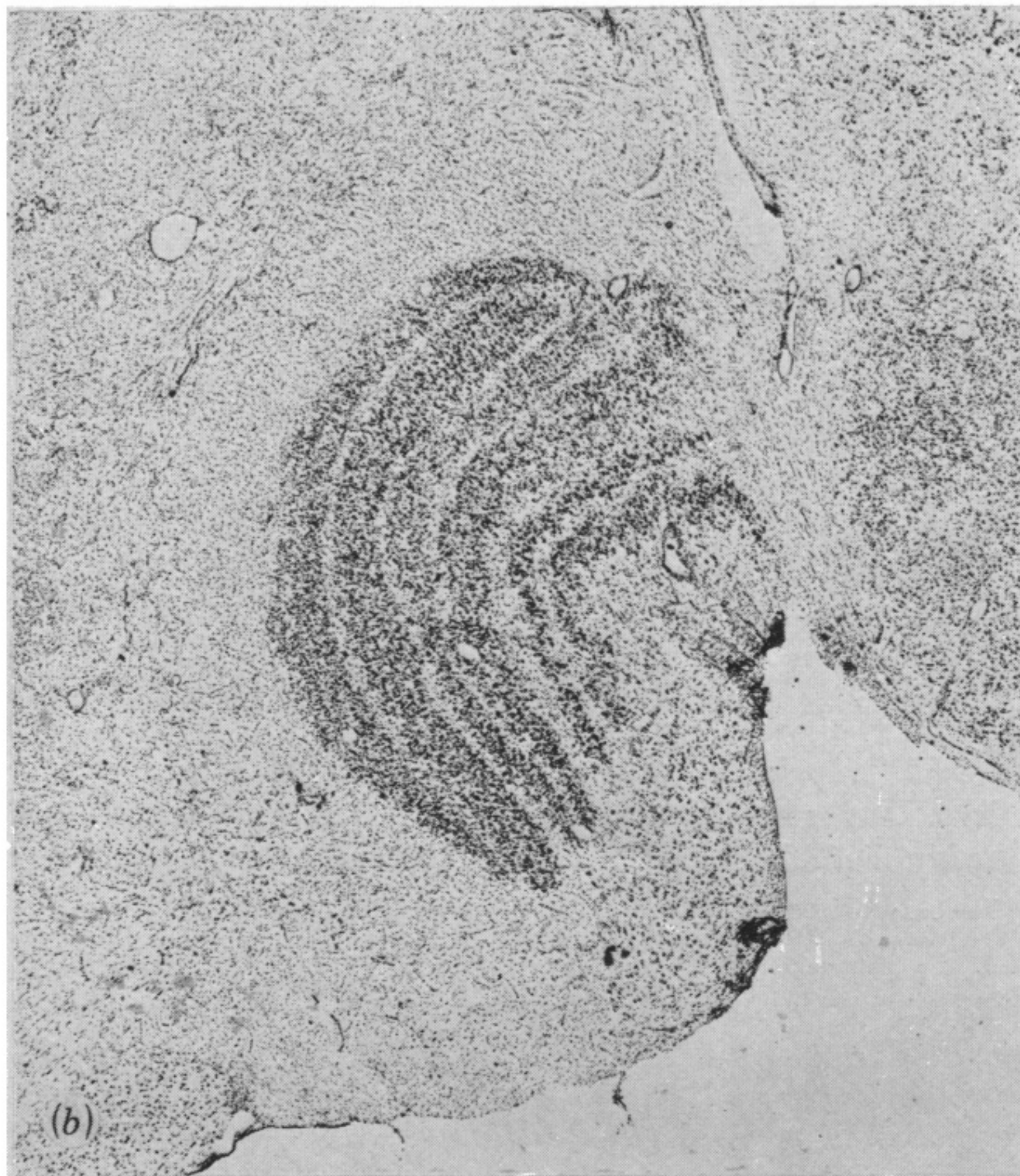
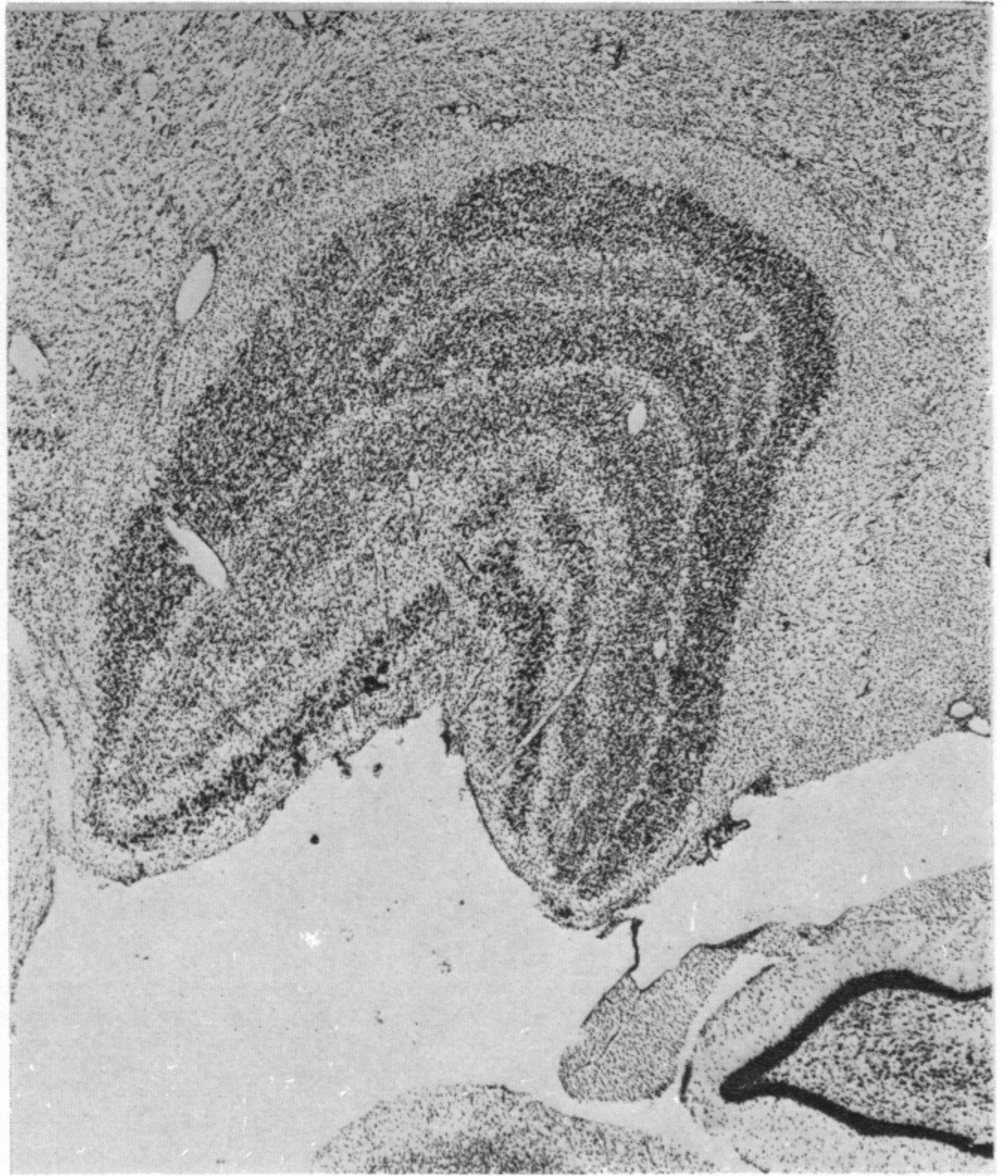
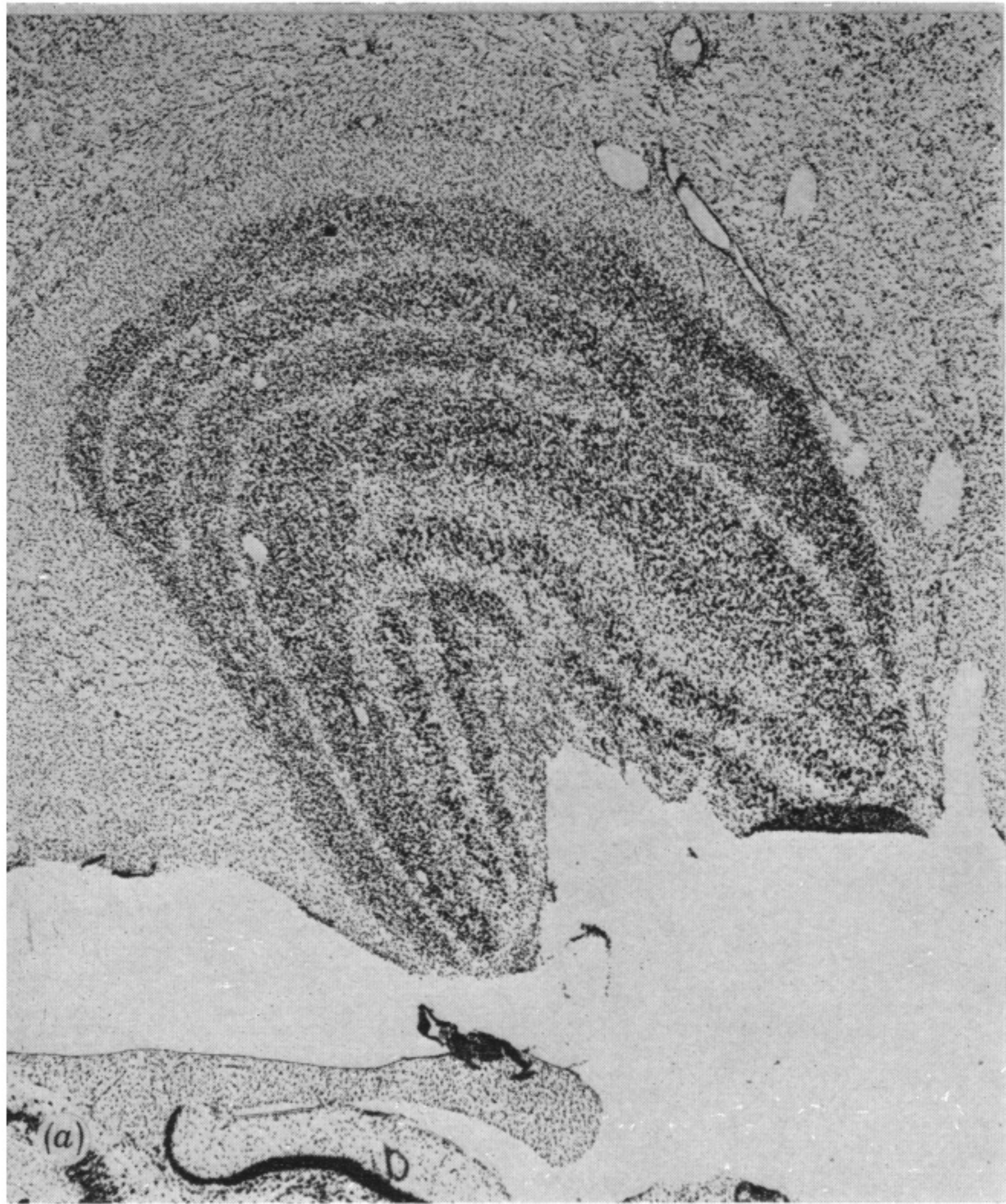


FIGURE 8. Coronal Nissl-stained sections through lateral geniculates of (a) Monkey no. 3, right eye closed at 2 weeks for 18 months. (b) Monkey no. 4, right eye closed at 3 weeks for 7 months. Note that the atrophy of the layers receiving input from the closed eye is more marked on the ipsilateral (right) side and more marked in *a* than in *b*. Cresyl violet; frozen sections.

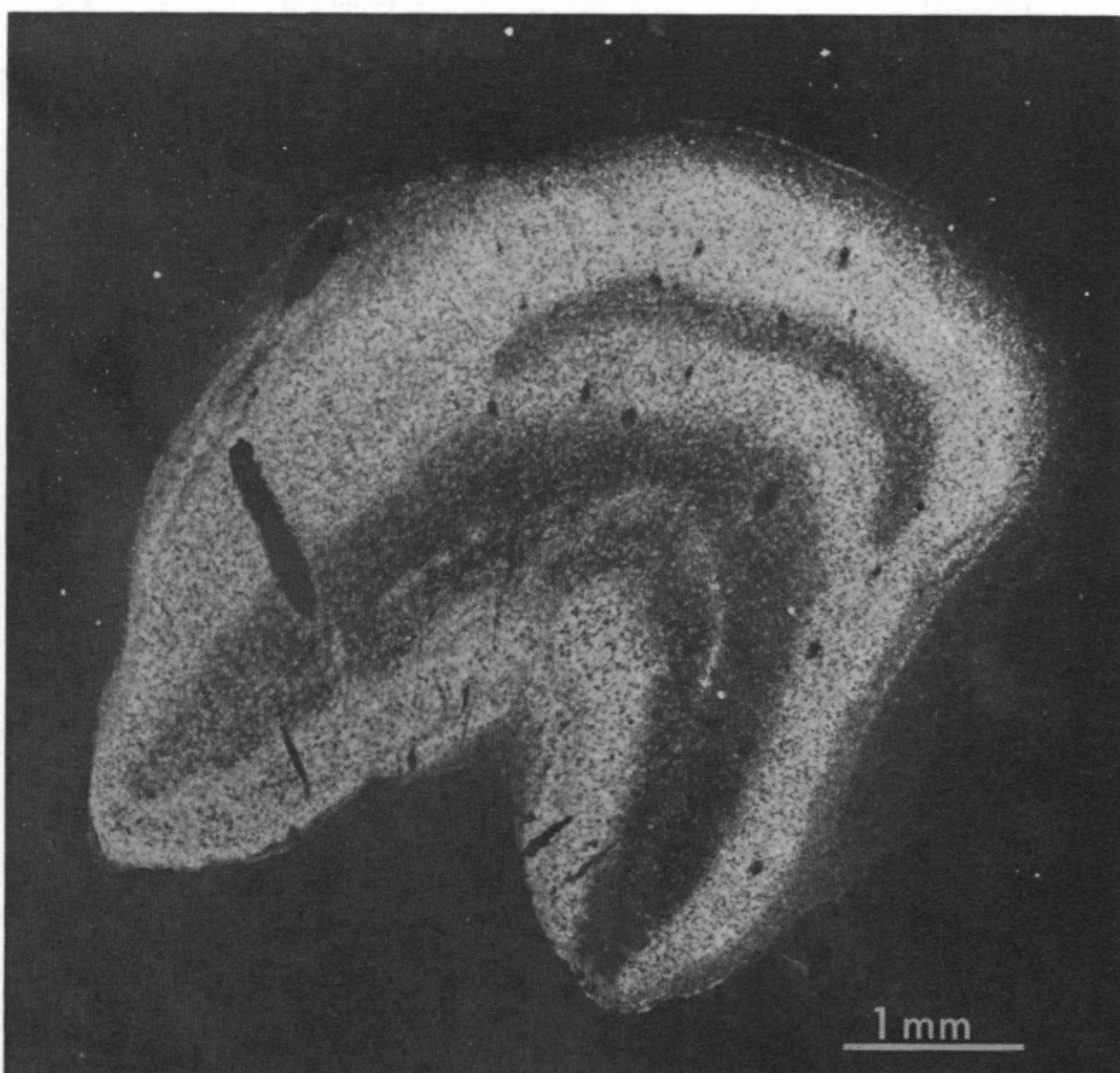
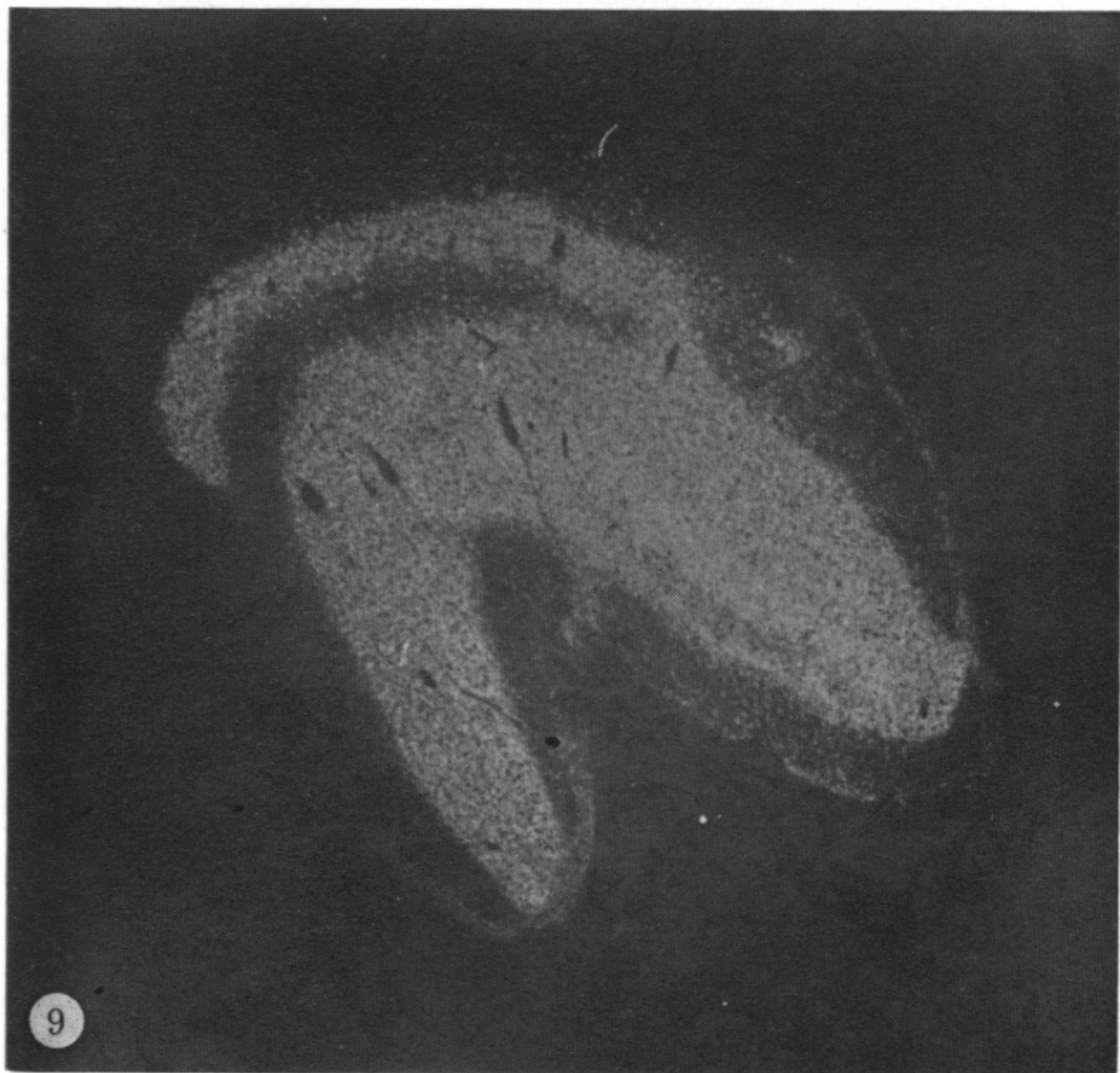
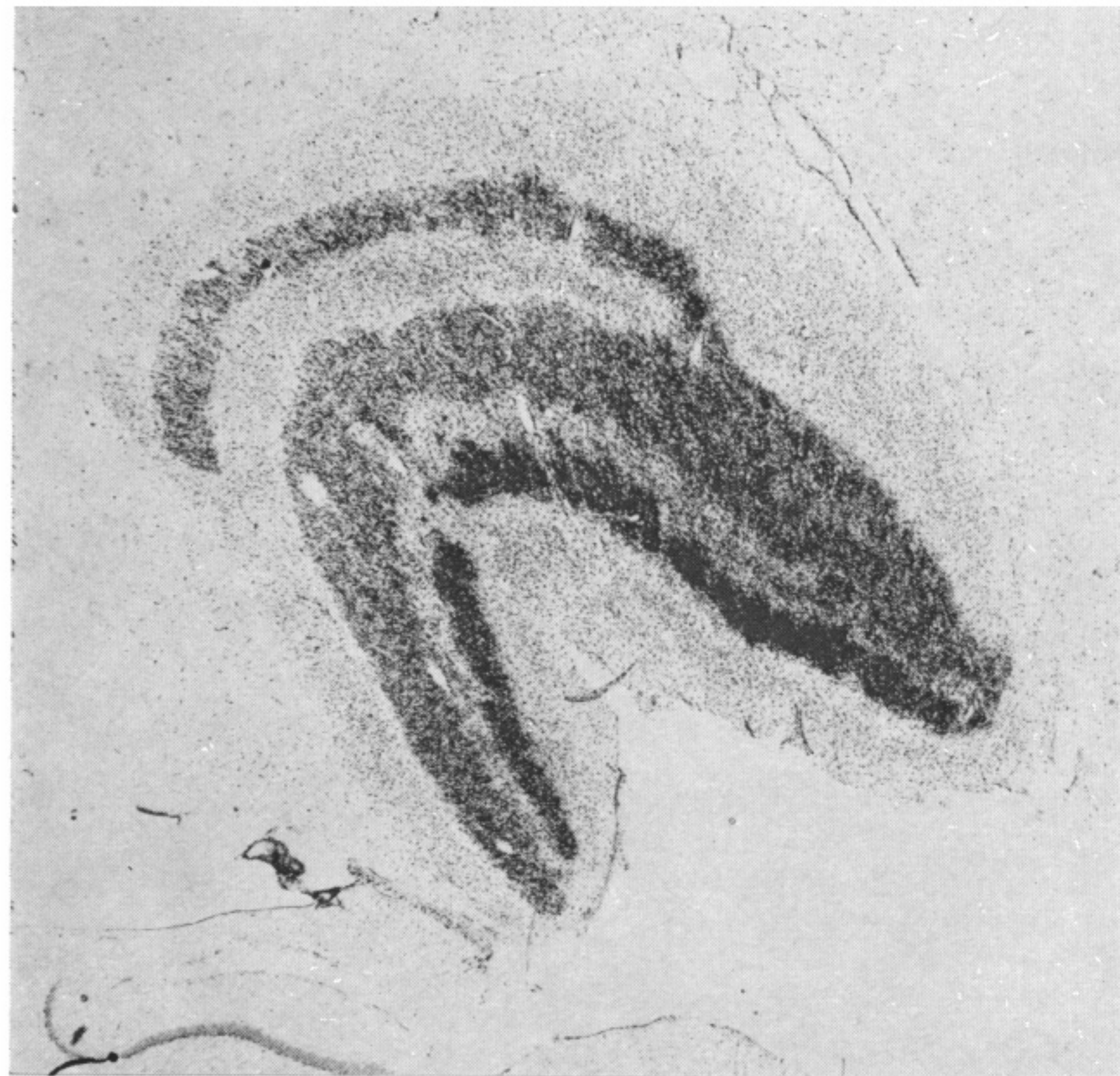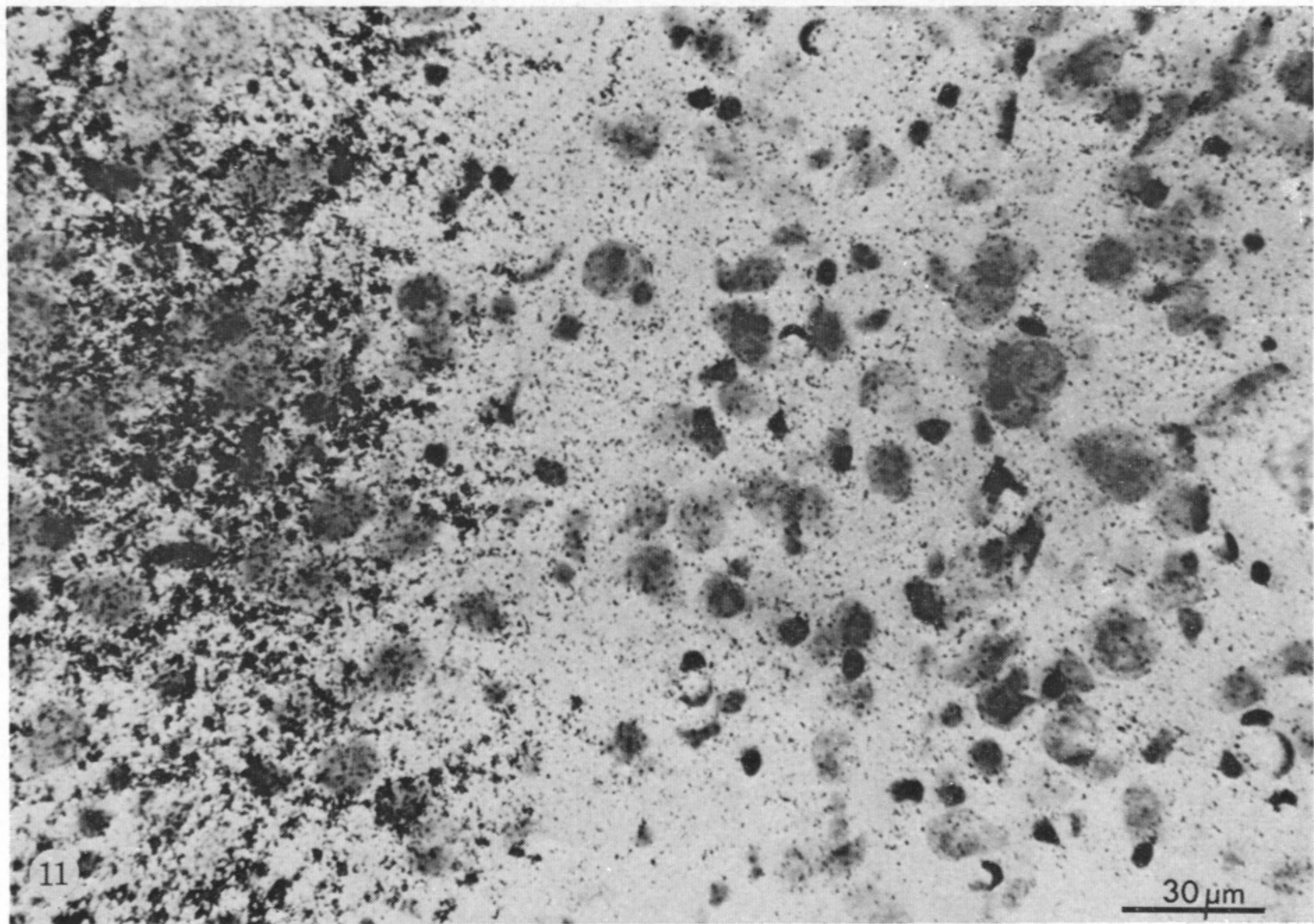
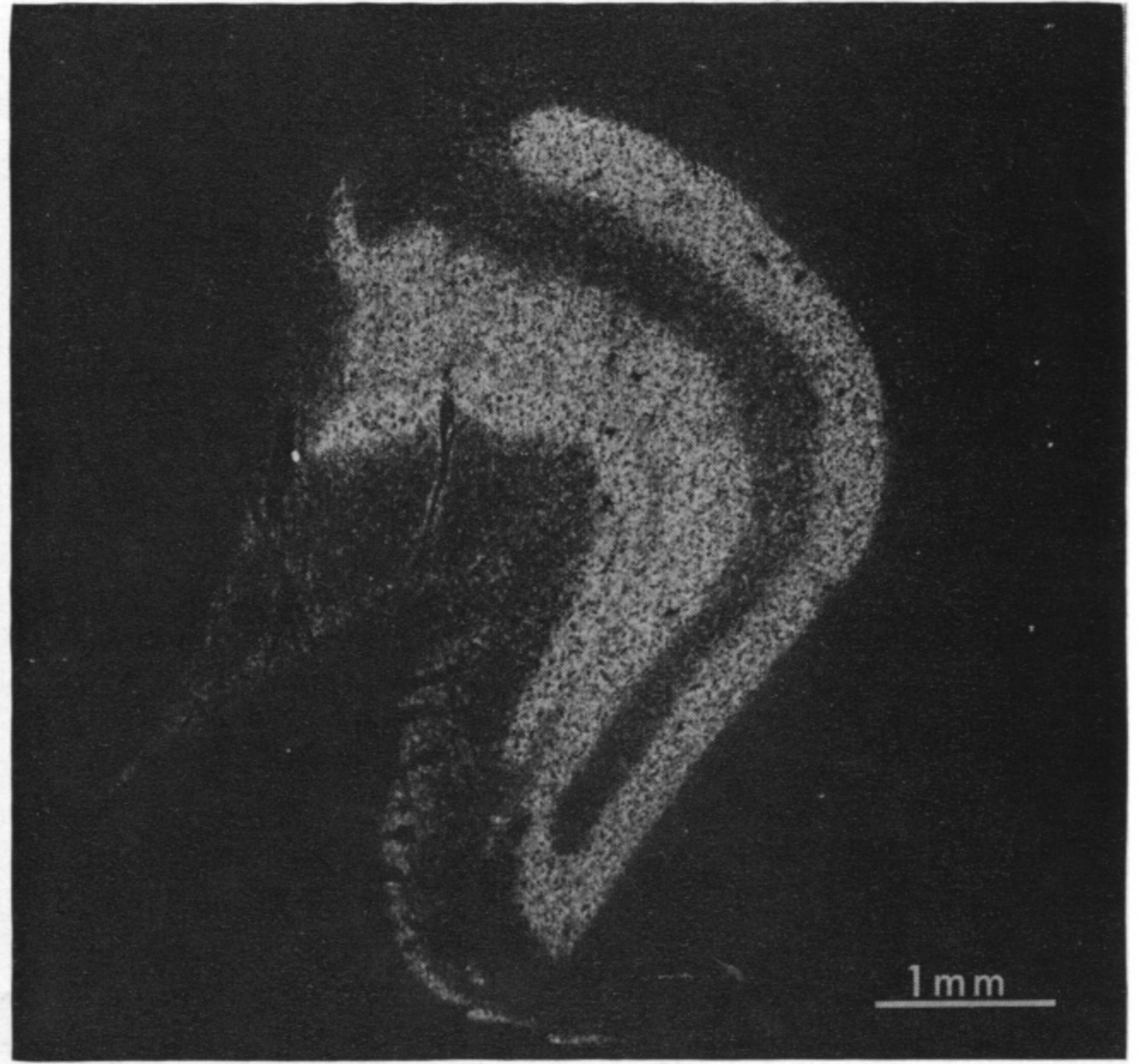
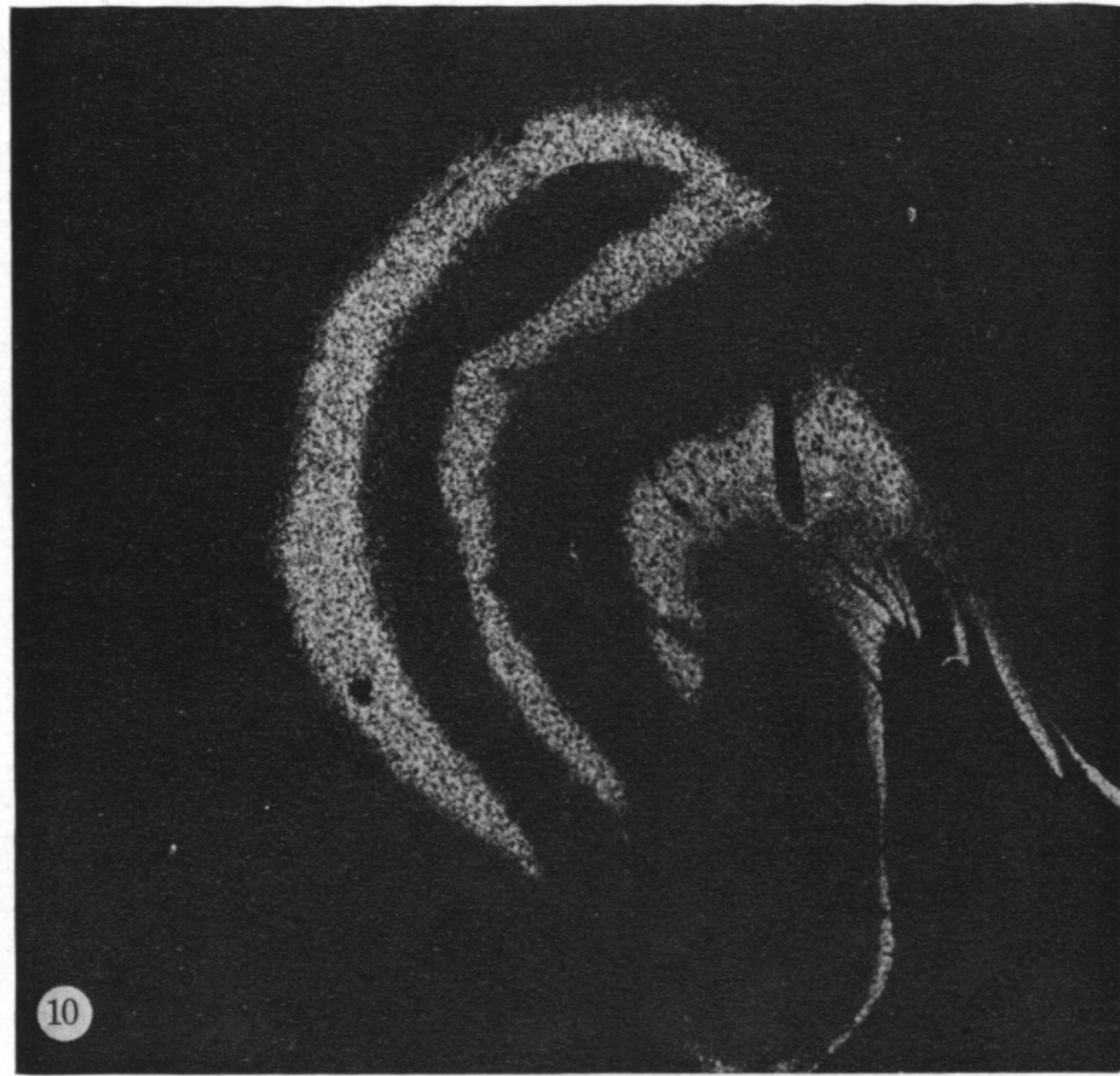
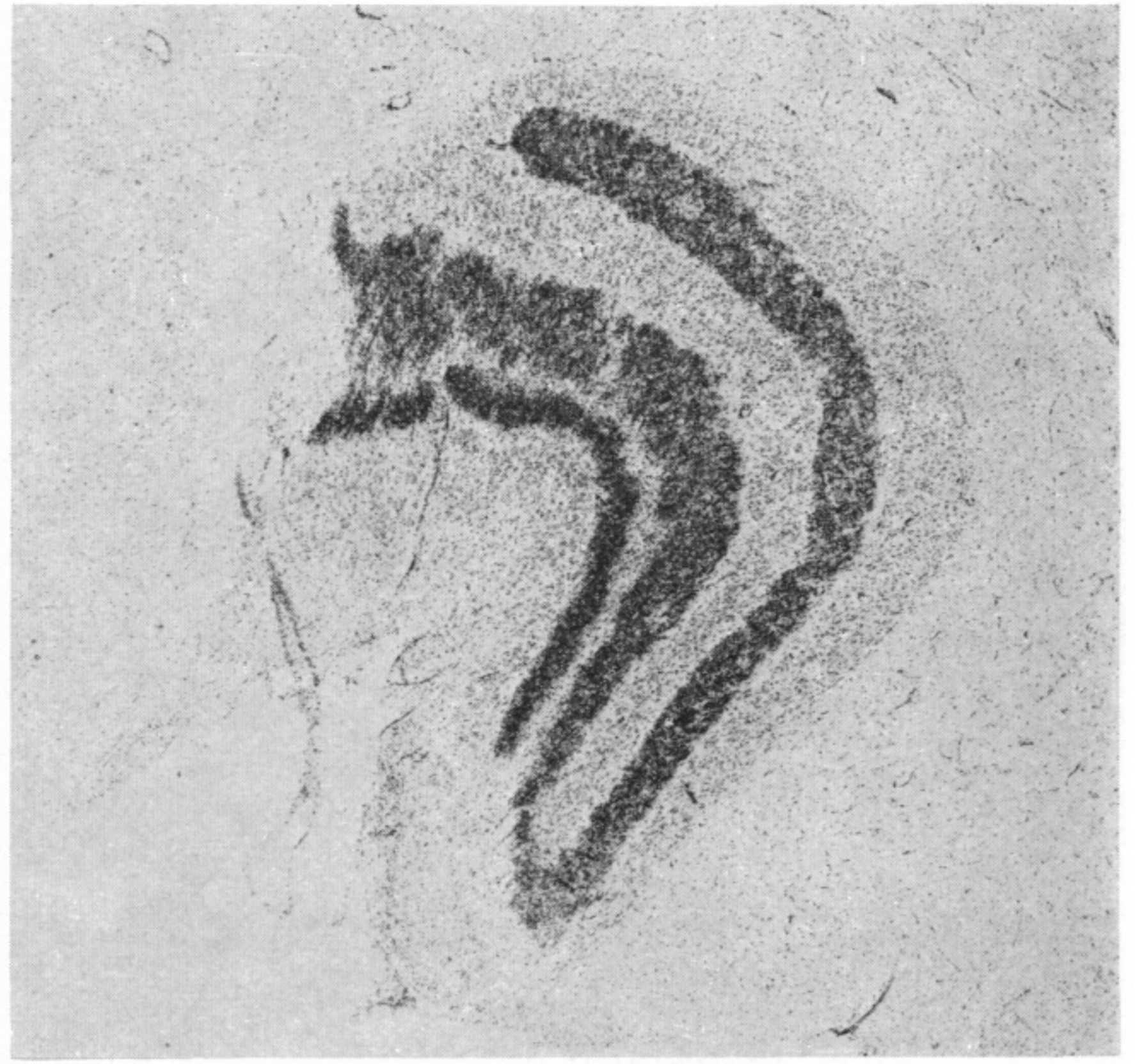
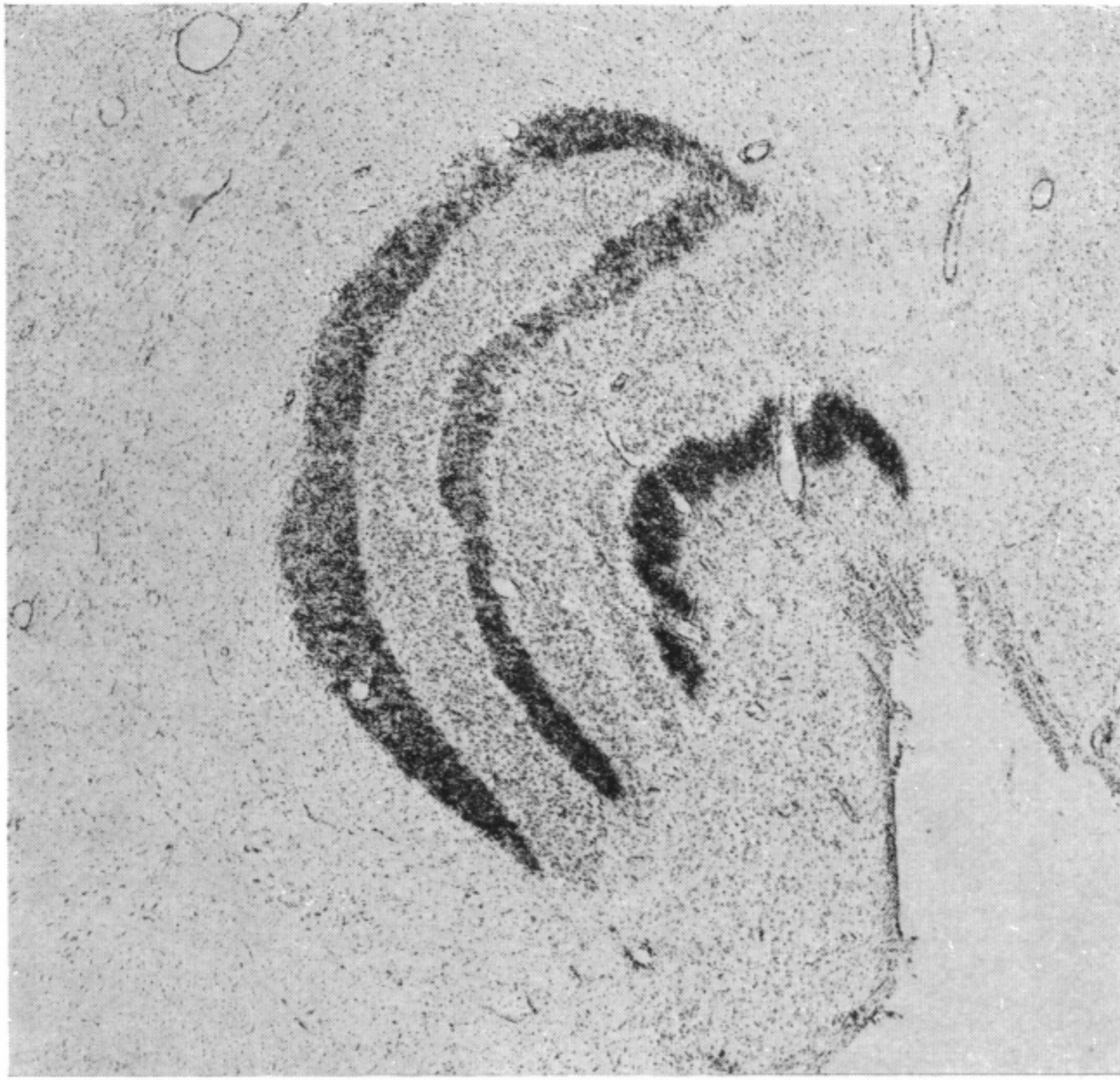


FIGURE 9. Autoradiographs of geniculates from monkey no. 3 (right eye closed at 2 weeks for 18 months) following injection of label into *left* (normal) eye. Coronal sections. Upper half, light-field, counterstained with cresyl violet. Lower half, dark-field of same sections. Note the band of label between classical layers 3 and 2, in the dark-field picture on the right (compare figure 24, layer *d*).



FIGURES 10 AND 11. For description see opposite.

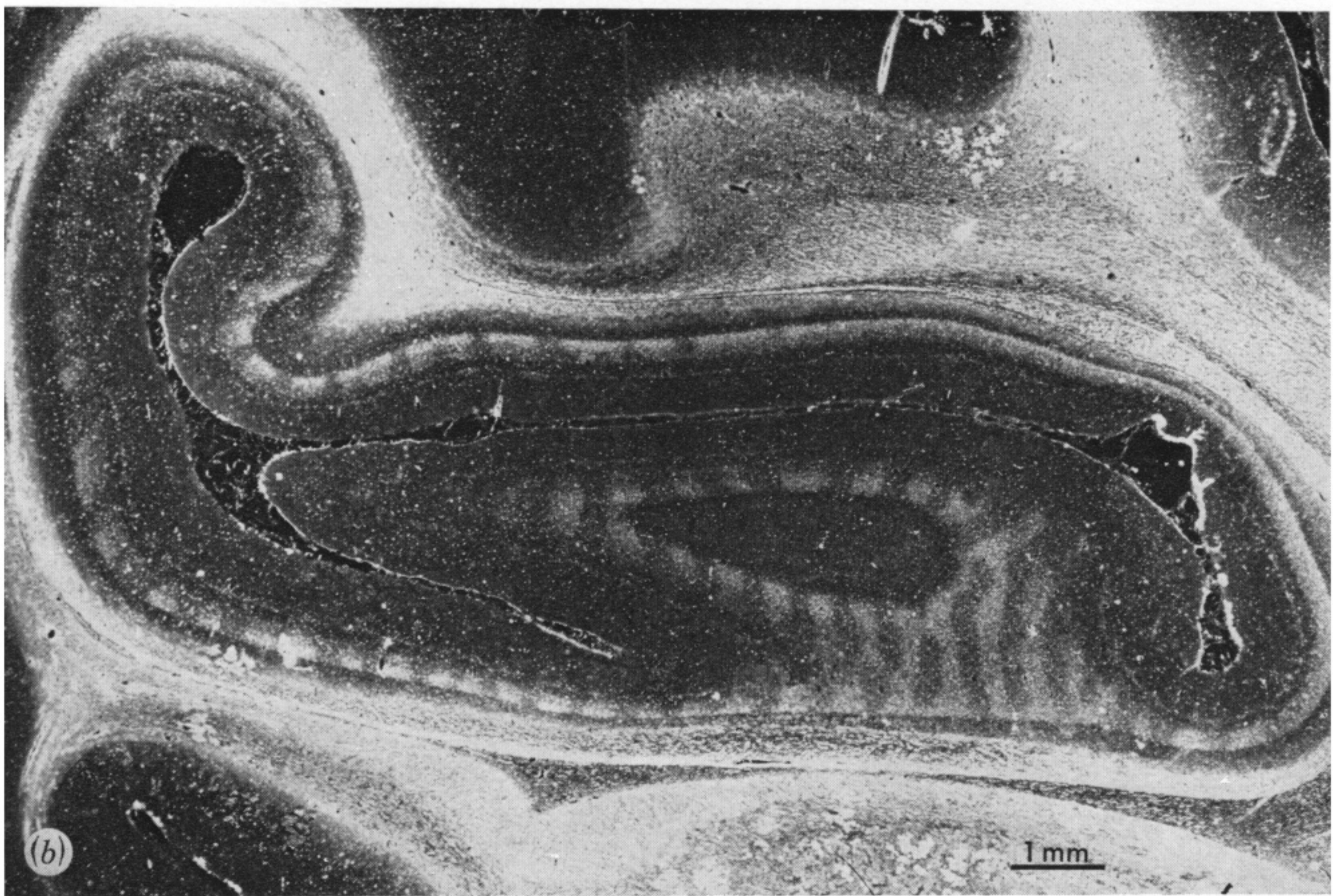
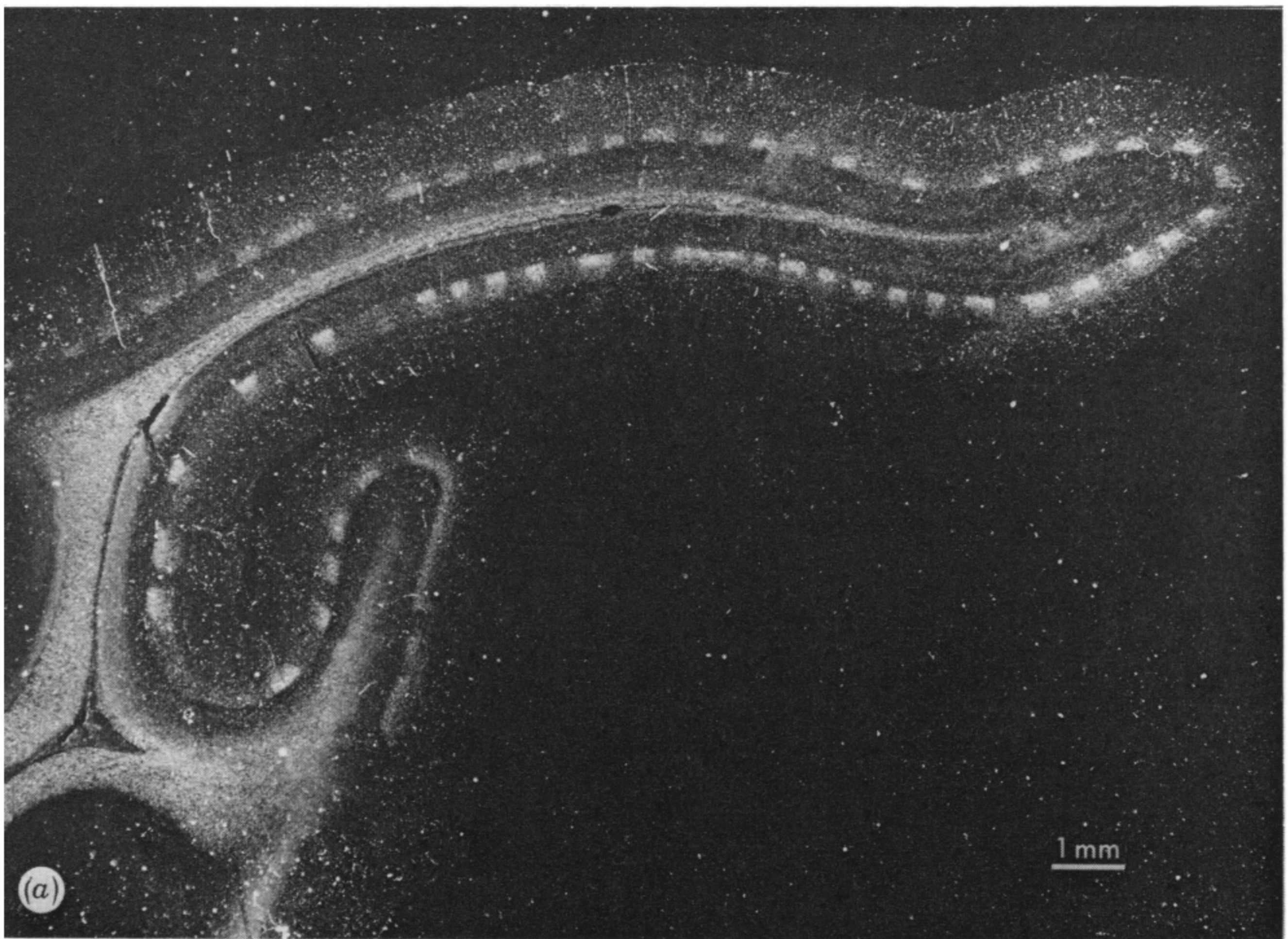
FIGURE 12. Dark-field autoradiographs of striate cortex in normal adult monkeys following right-eye injection of radioactive fucose-proline mixture 2 weeks before. (a) Transverse section through right striate cortex, perpendicular to occipital operculum, in a plane normal to the sagittal, tipped back from coronal by about 45° . Labelled bands can be clearly made out in layer IV C. In the finger-like gyrus, the opercular cortex above and the superior bank of the calcarine fissure below are separated by a brightly labelled continuous band; this represents the optic radiations. (The lower bank of the calcarine fissure has fallen away.) Medial is to the right. (Monkey no. 7.) (b) Parasagittal section through the buried calcarine cortex contralateral to the injected eye; most of the cortex is cut in a plane perpendicular to the layers, but one fold is intersected tangentially, and here the layer IV C columns are seen as parallel bands. The upper tier in layer IV A can just be made out in most places. The stretch of continuous label in layer IV C in the upper right part of the ring represents the temporal crescent. Anterior is up and to the right; the operculum would be just to the left of the figure. (Monkey no. 6.)


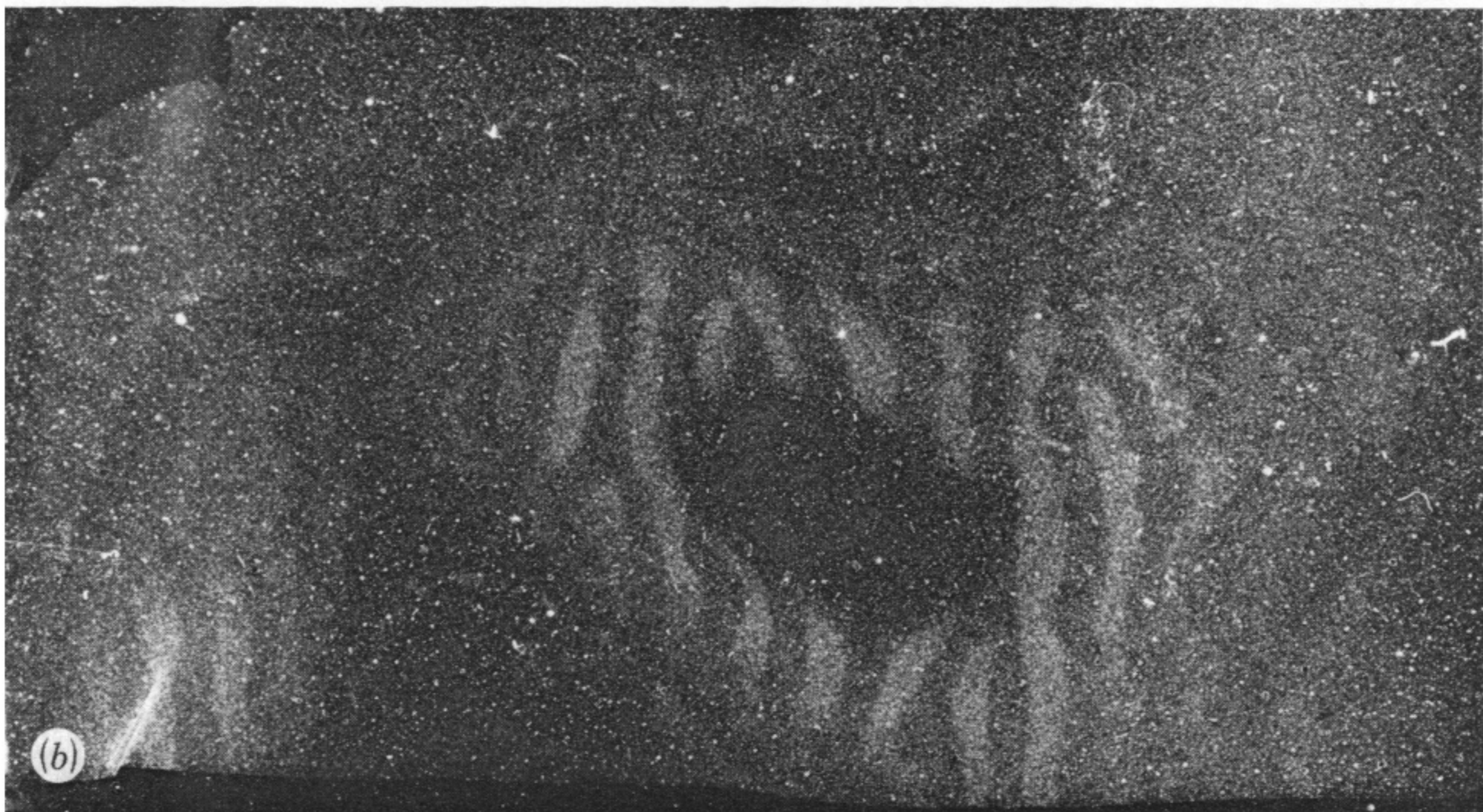

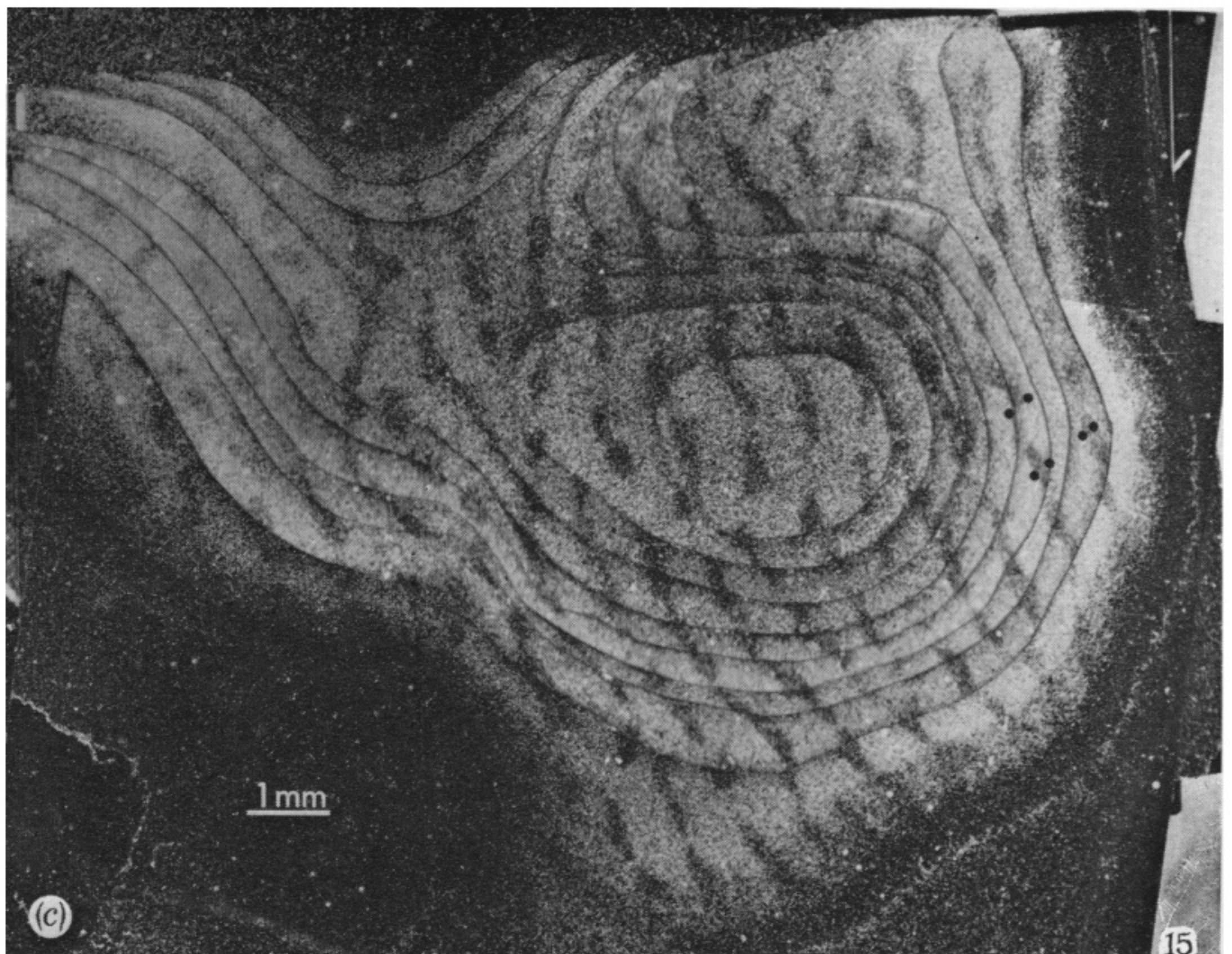
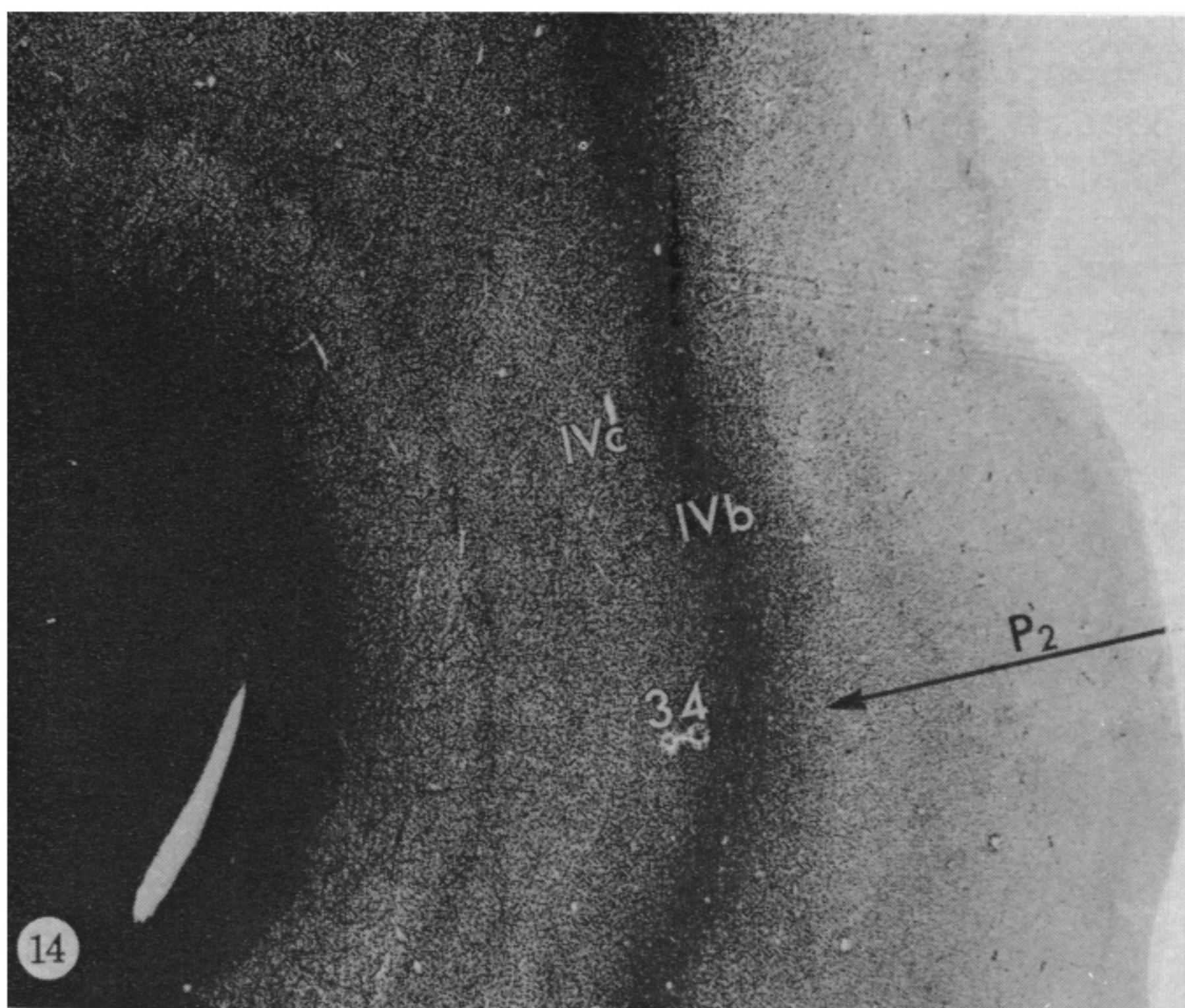
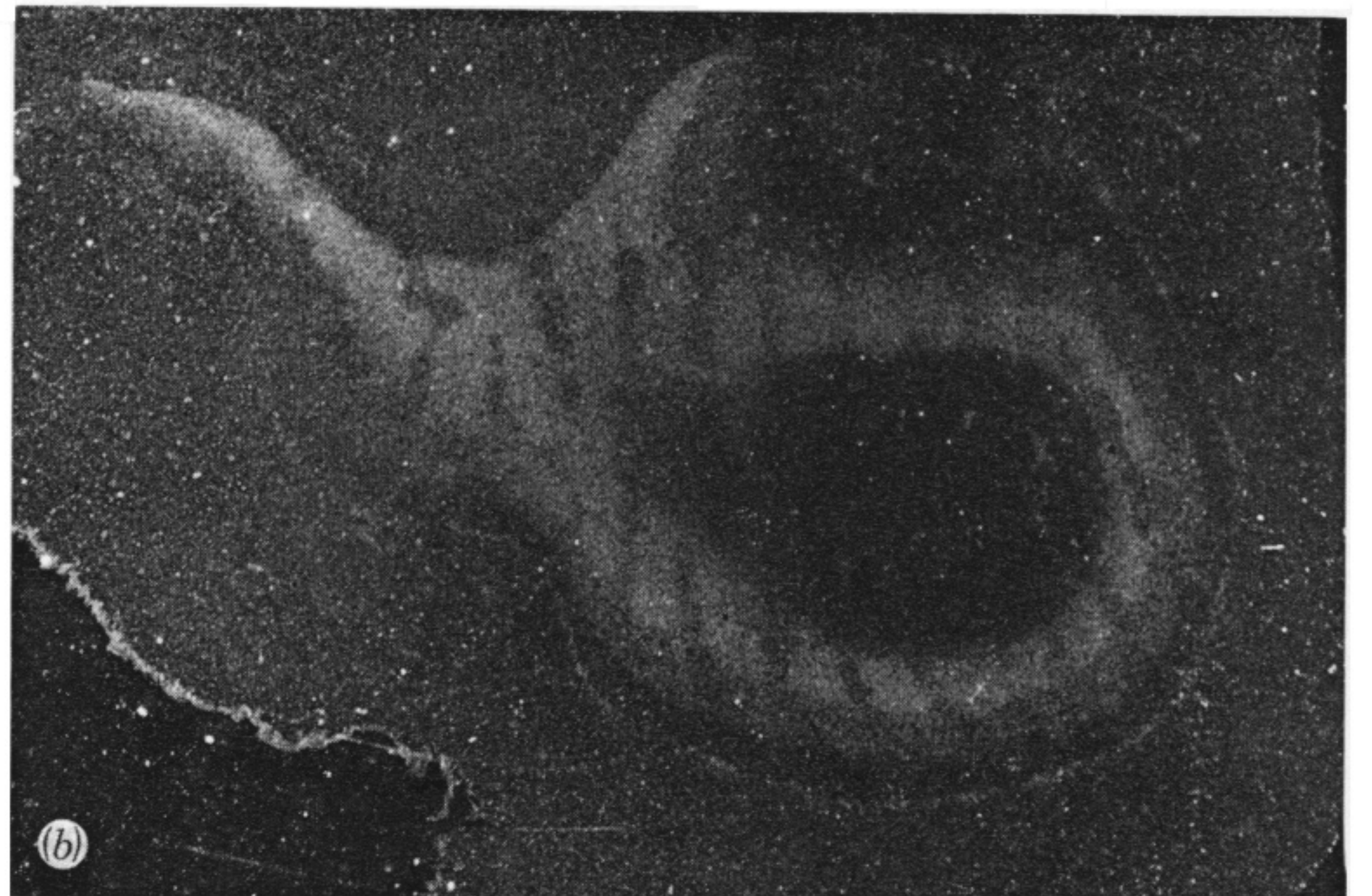
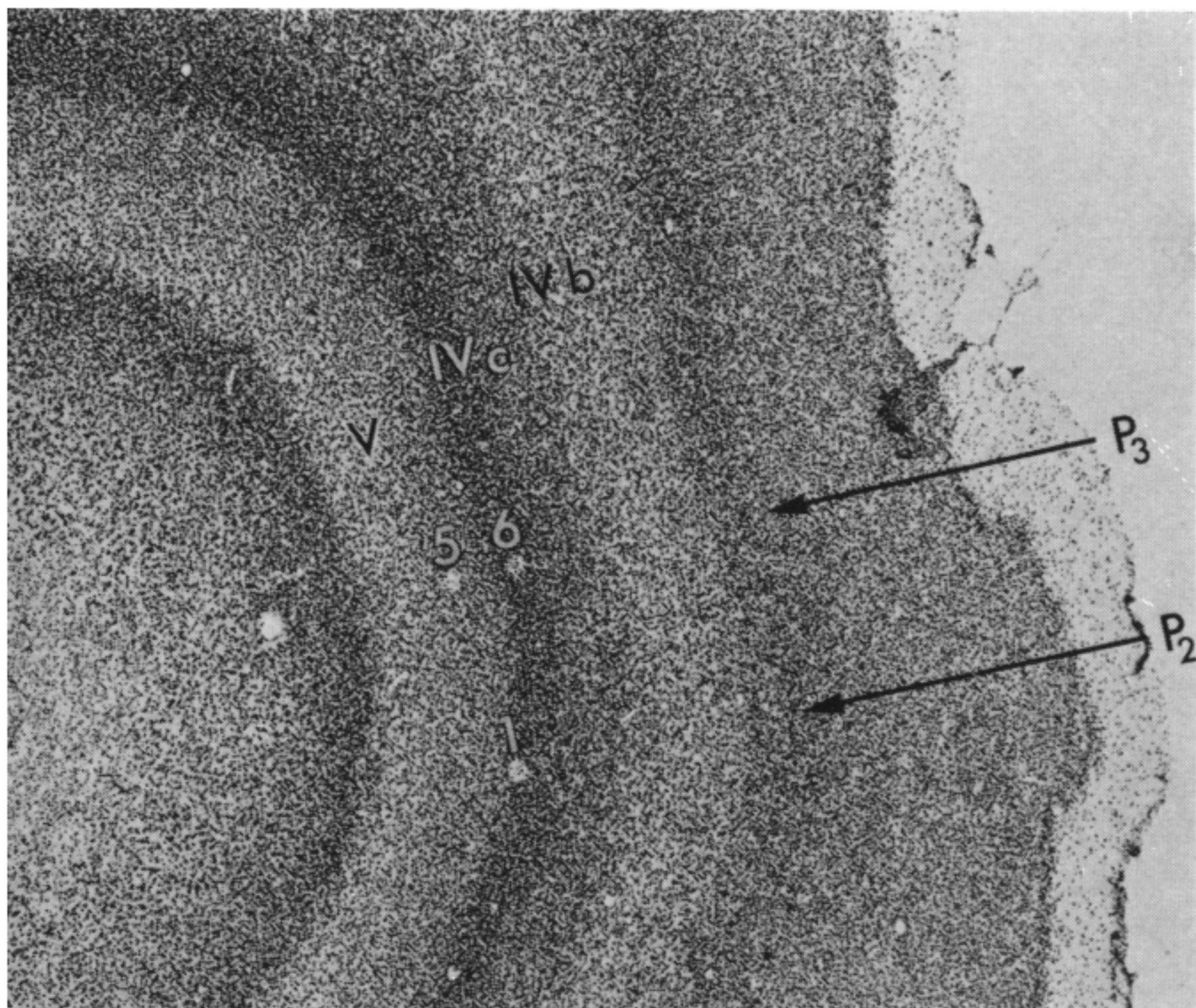
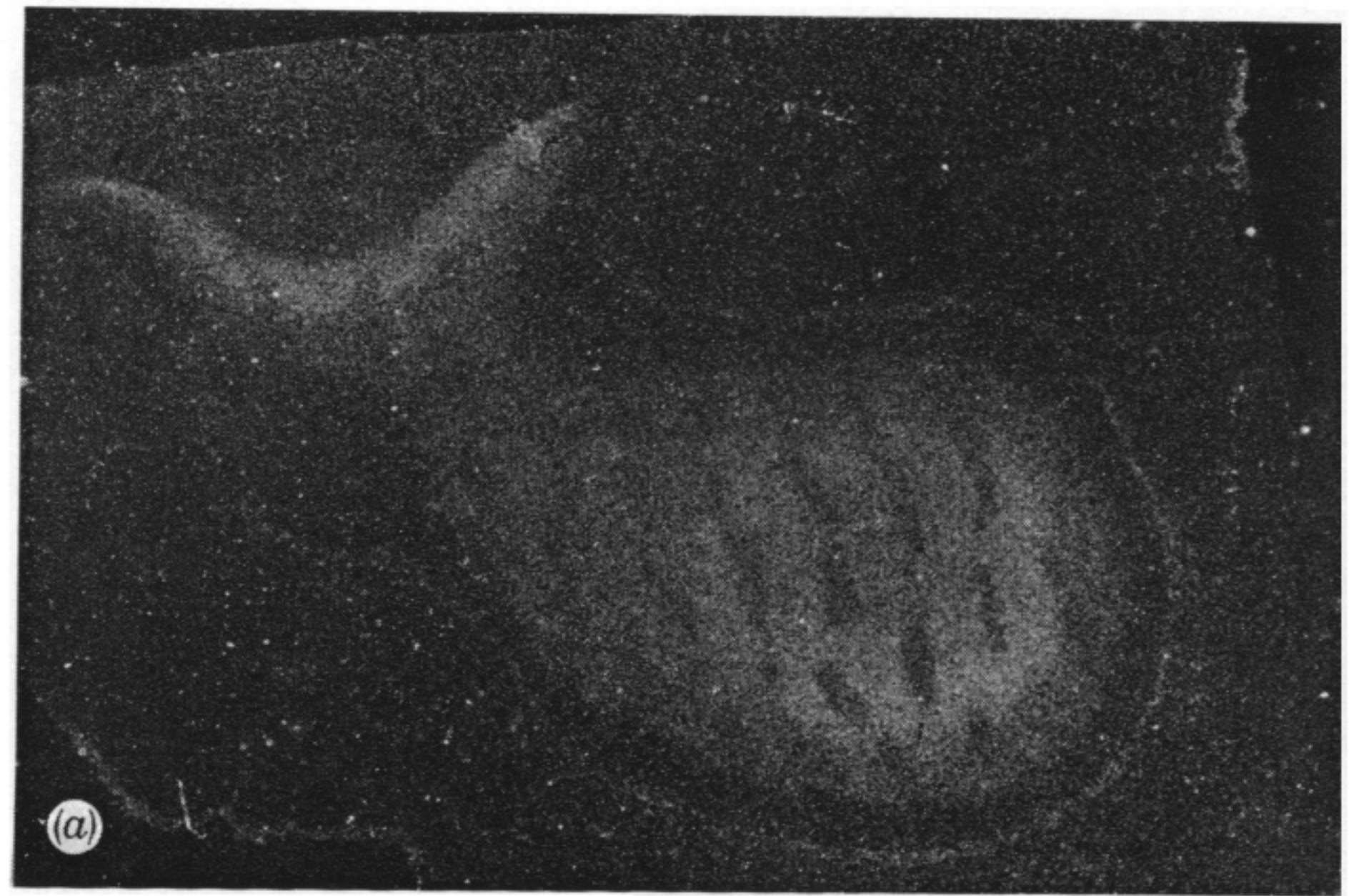
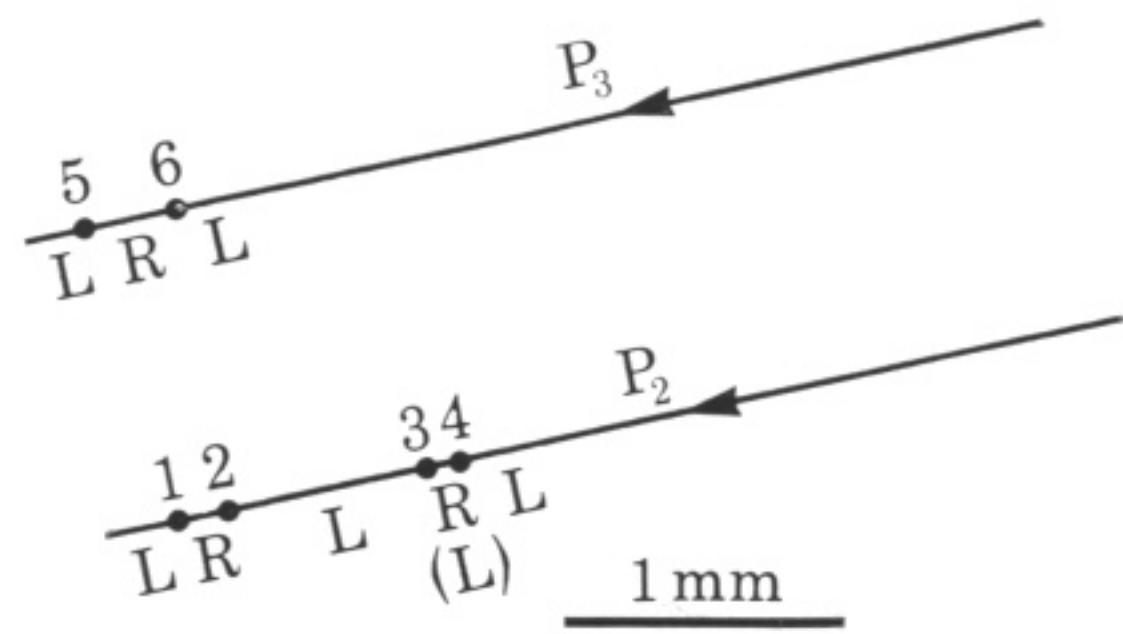
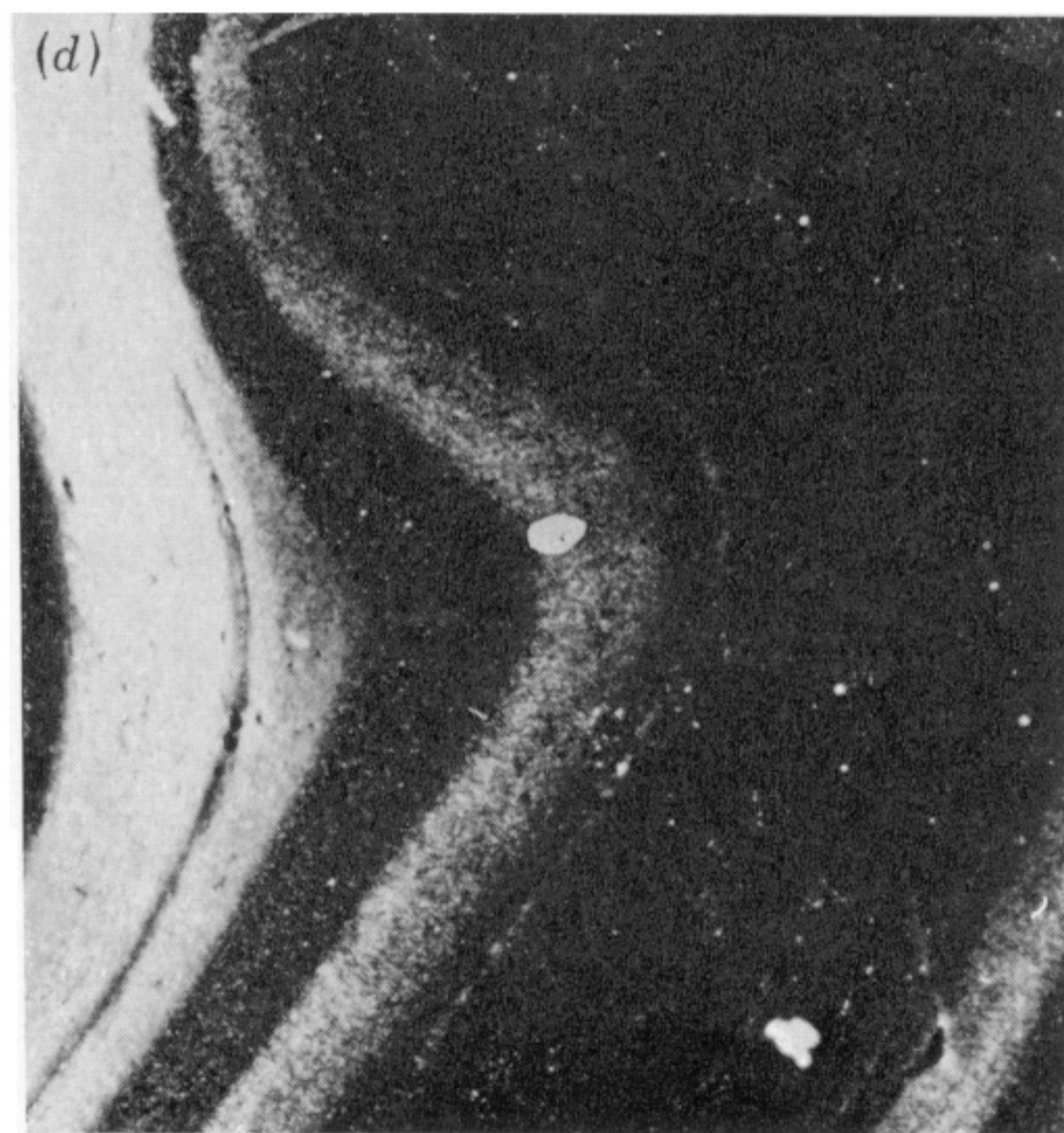

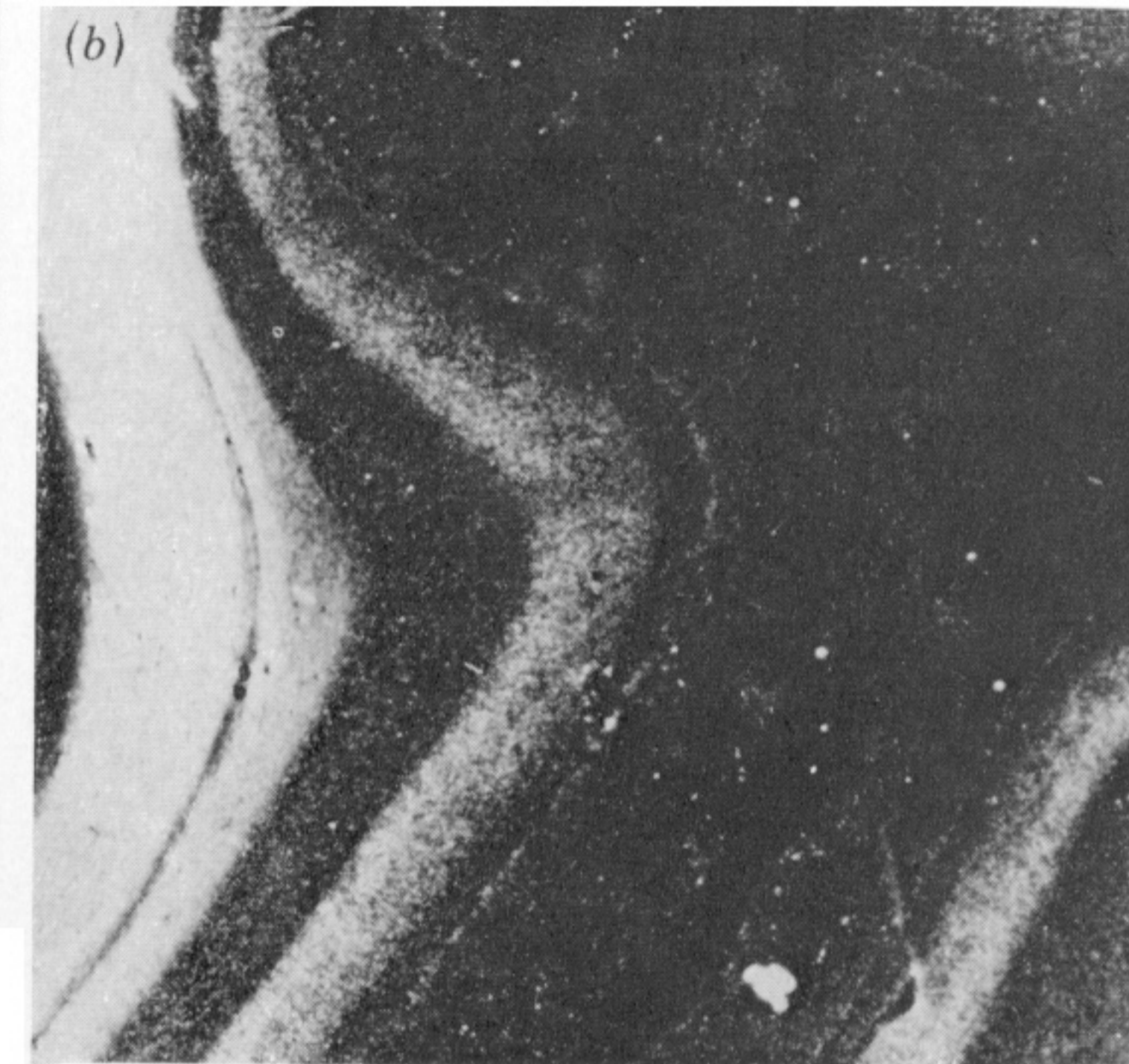
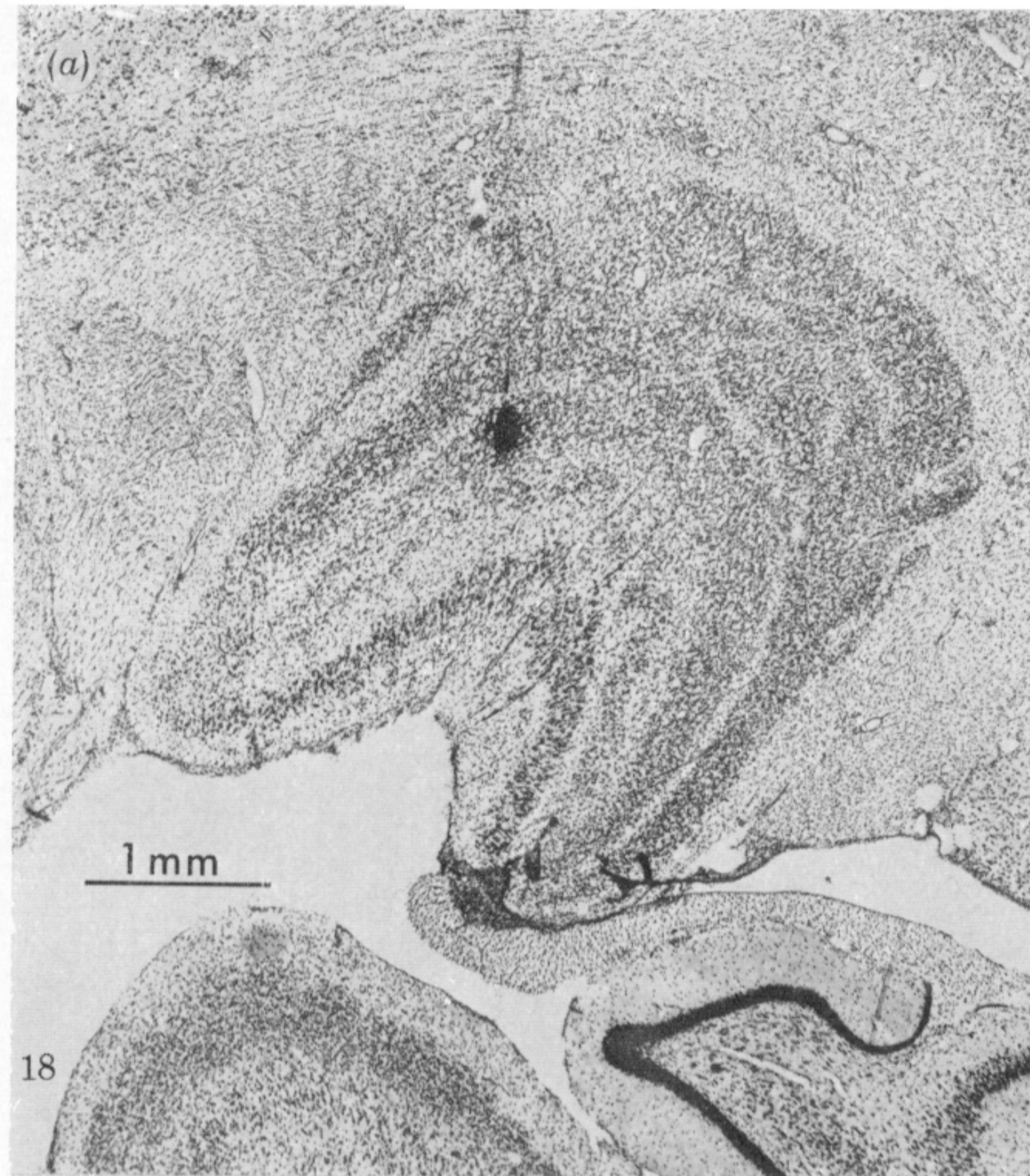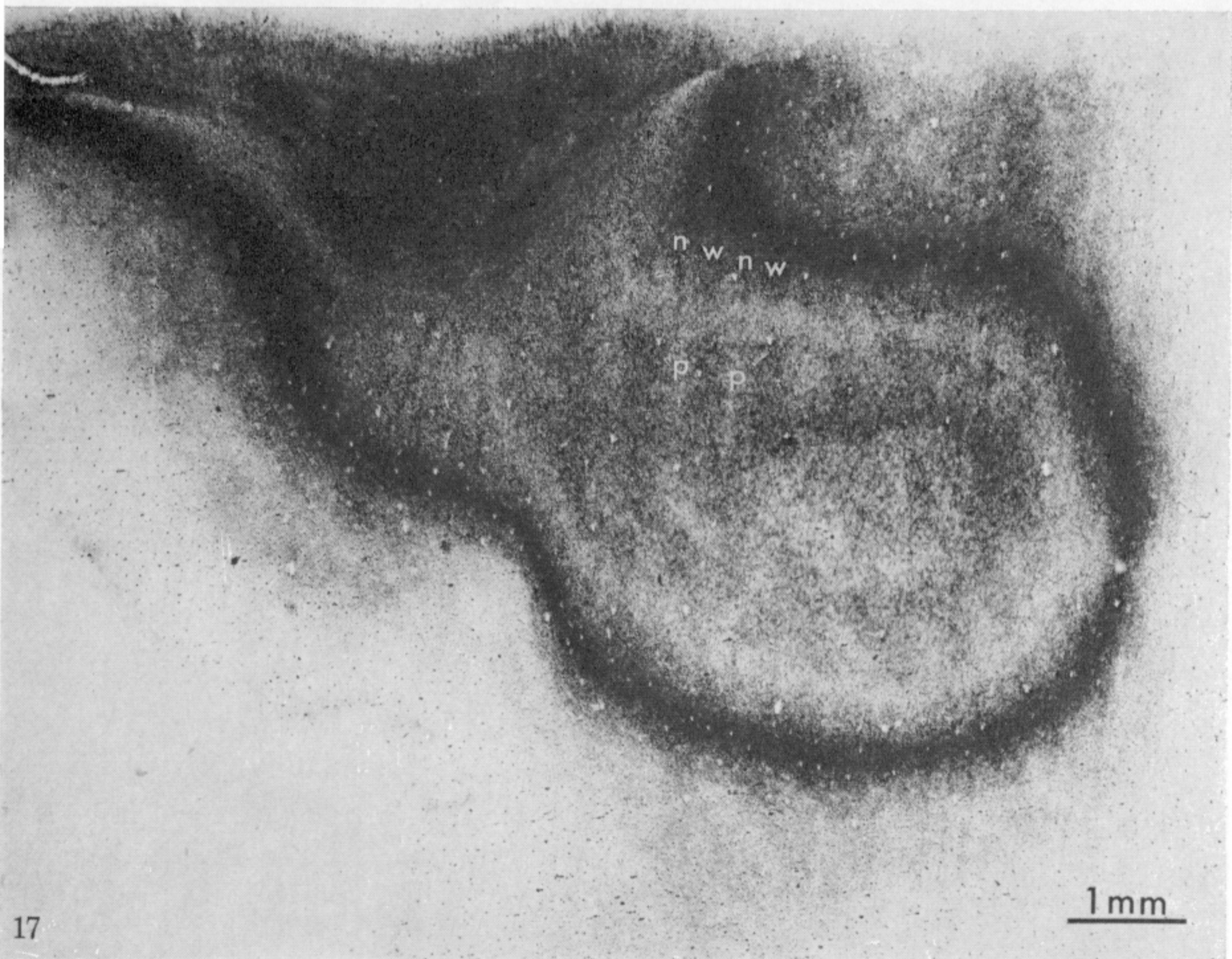
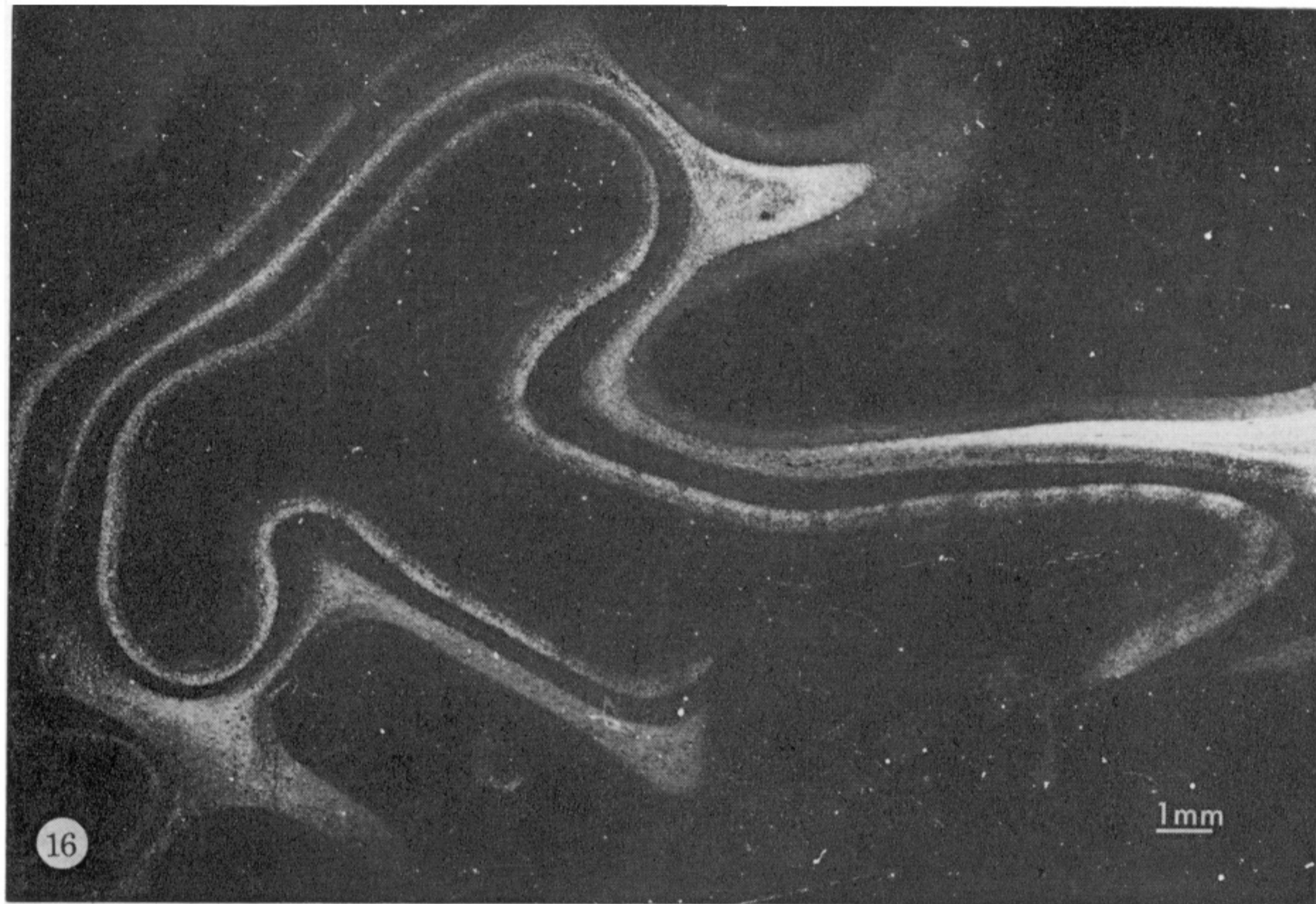


FIGURE 13. Normal monkey (no. 7). Autoradiographs taken in dark field, of tangential sections through the dome shaped exposed surface of the right occipital lobe (operculum), ipsilateral to the injected (right) eye. The section shown in (a) passes tangential to layer IV C, which is seen as a series of light stripes, representing the labelled right-eye columns, separated by gaps of the same width representing the left eye. (b) is some 160 μm deeper than a, passing tangential to layer V and showing layer IV C as a ring of dark and light stripes into which the oval of a can be fitted. (c) is a reconstruction made by fitting together eight parallel sections including those of a and b. Anterior is up, medial to the left.



FIGURES 14 AND 15. For description see opposite.



FIGURES 16-18. For description see opposite.

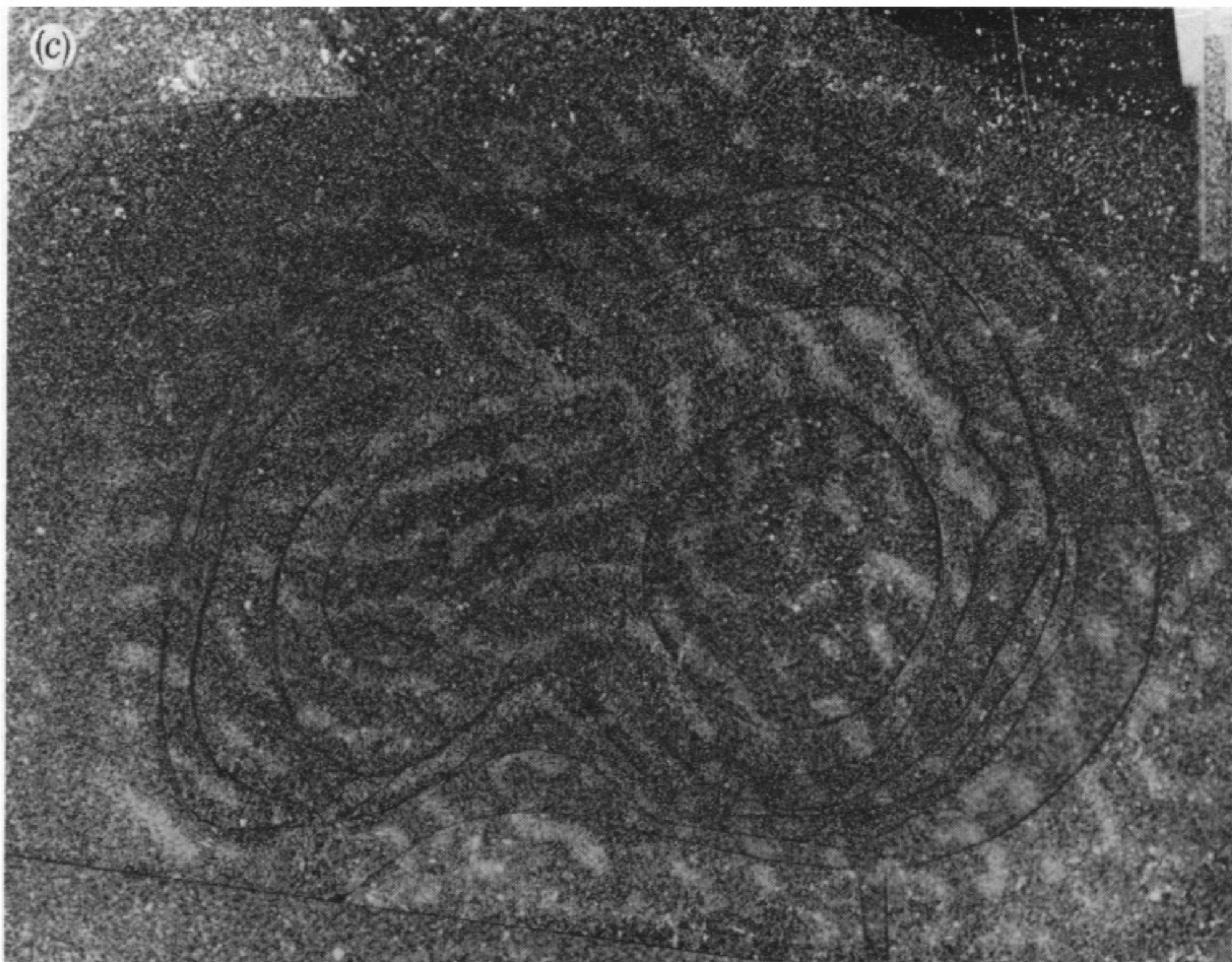
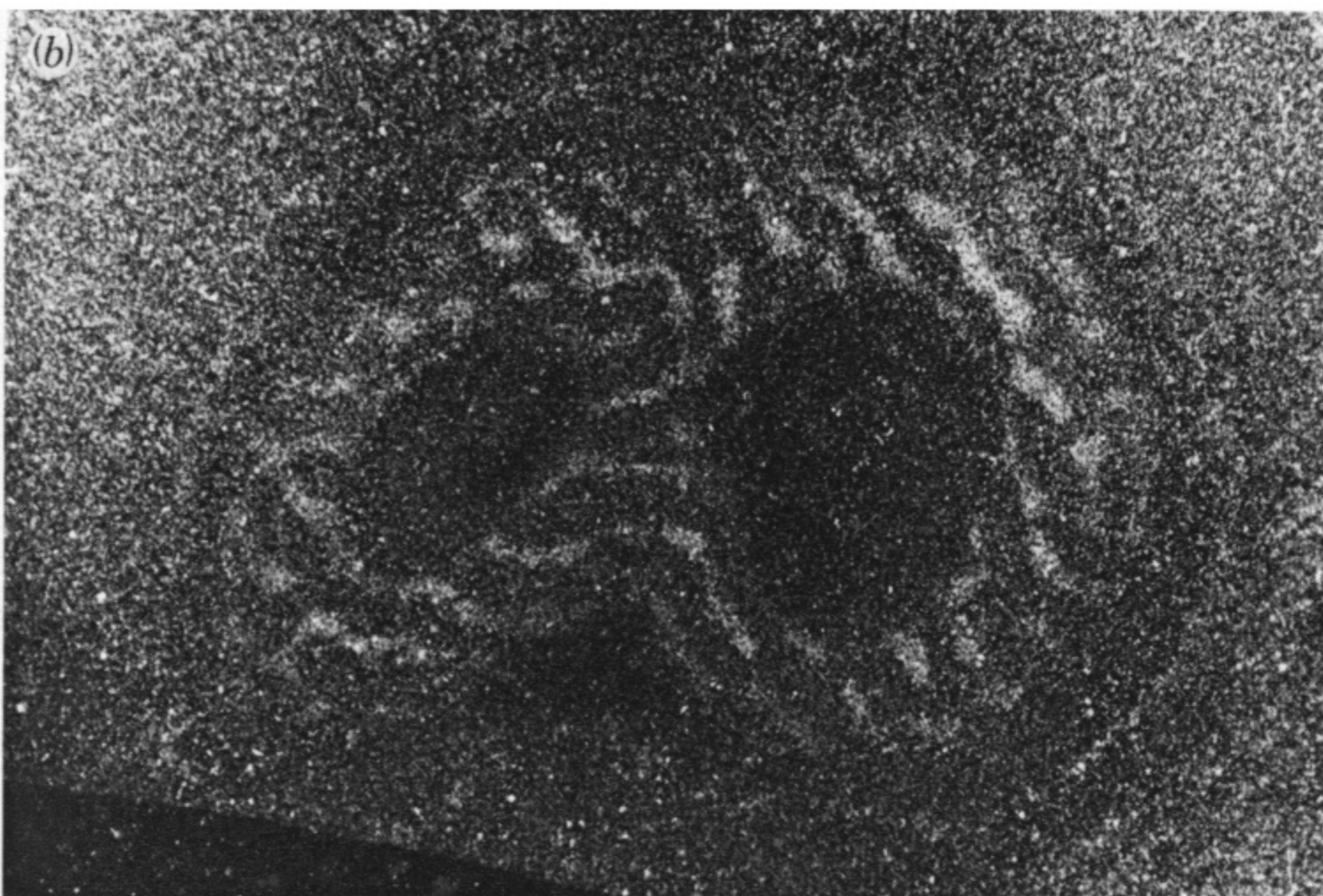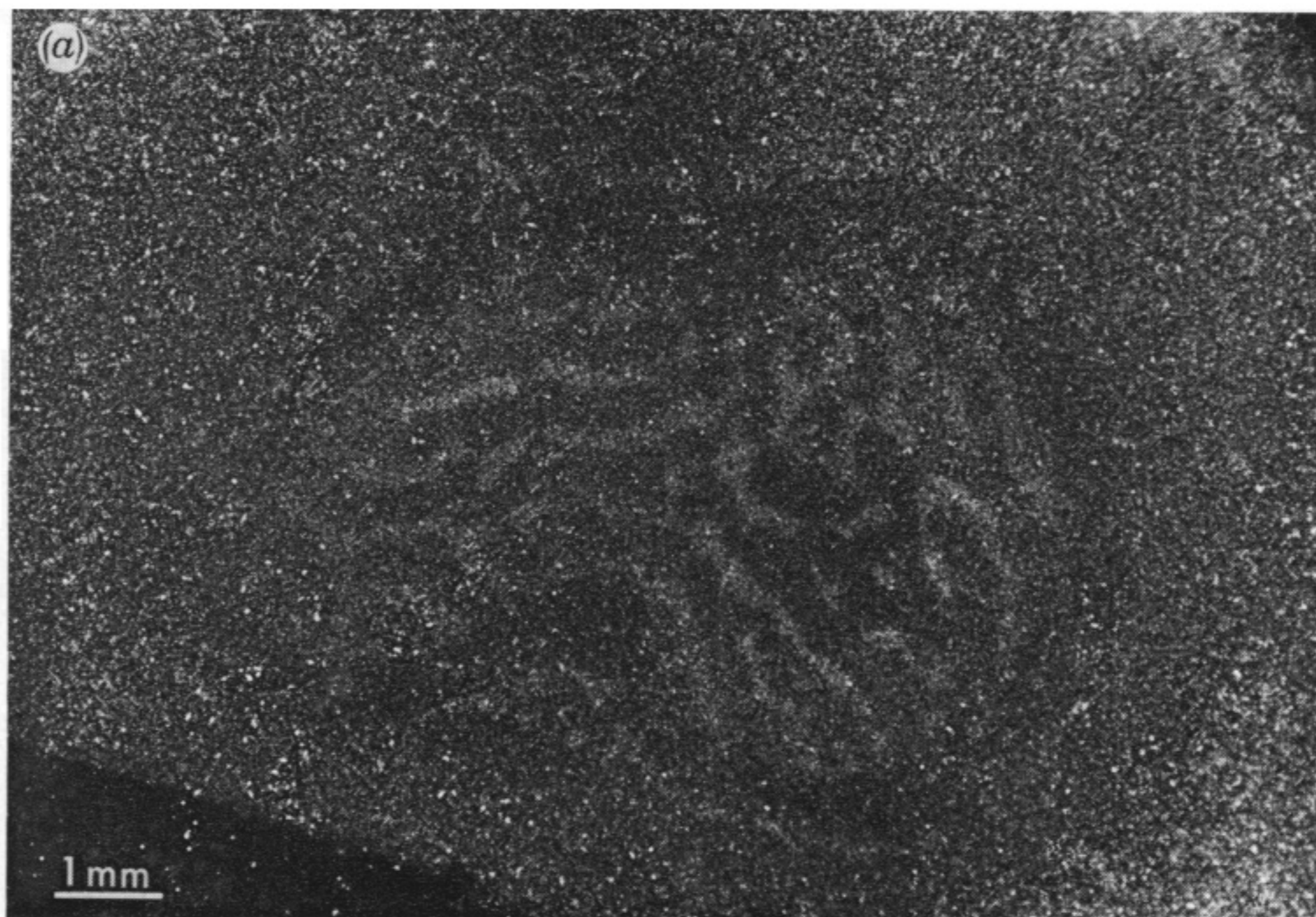
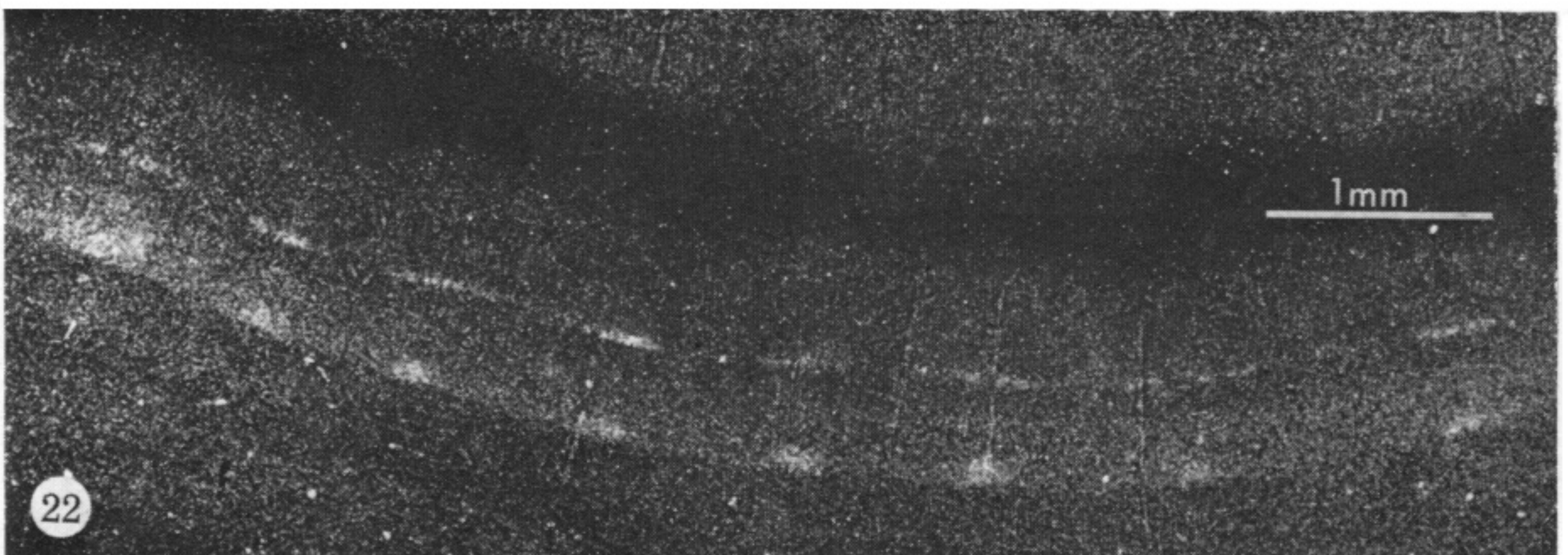
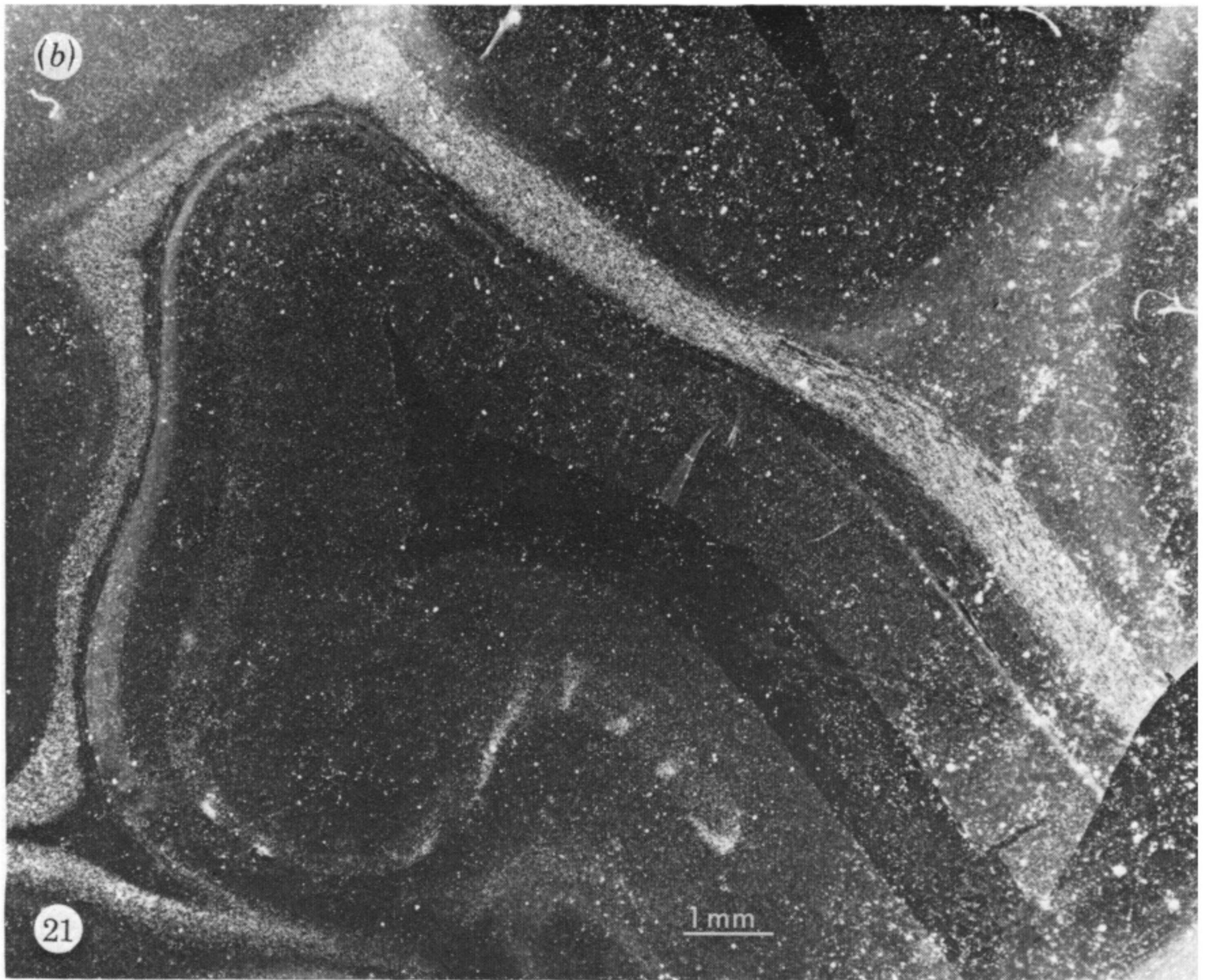
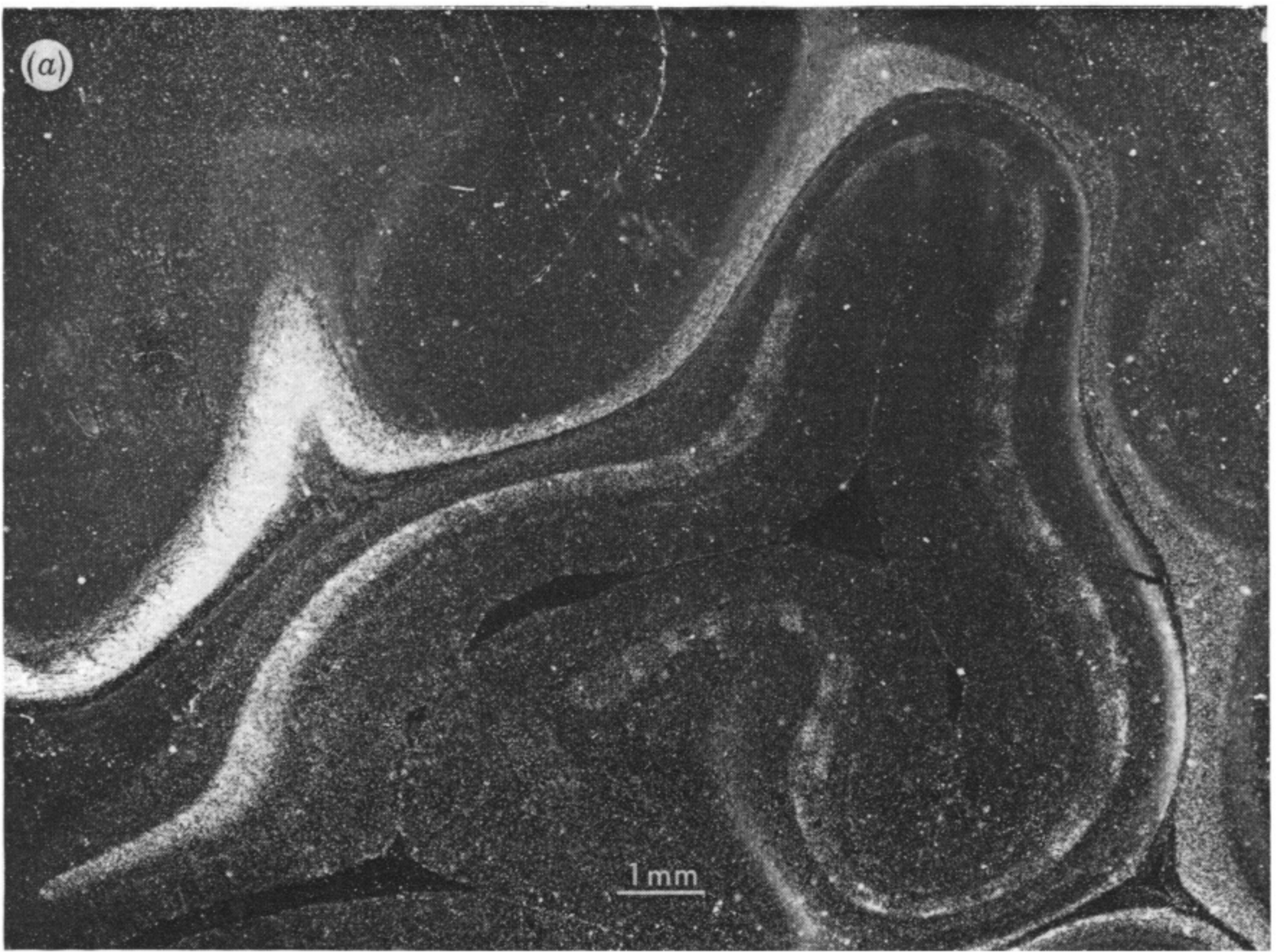
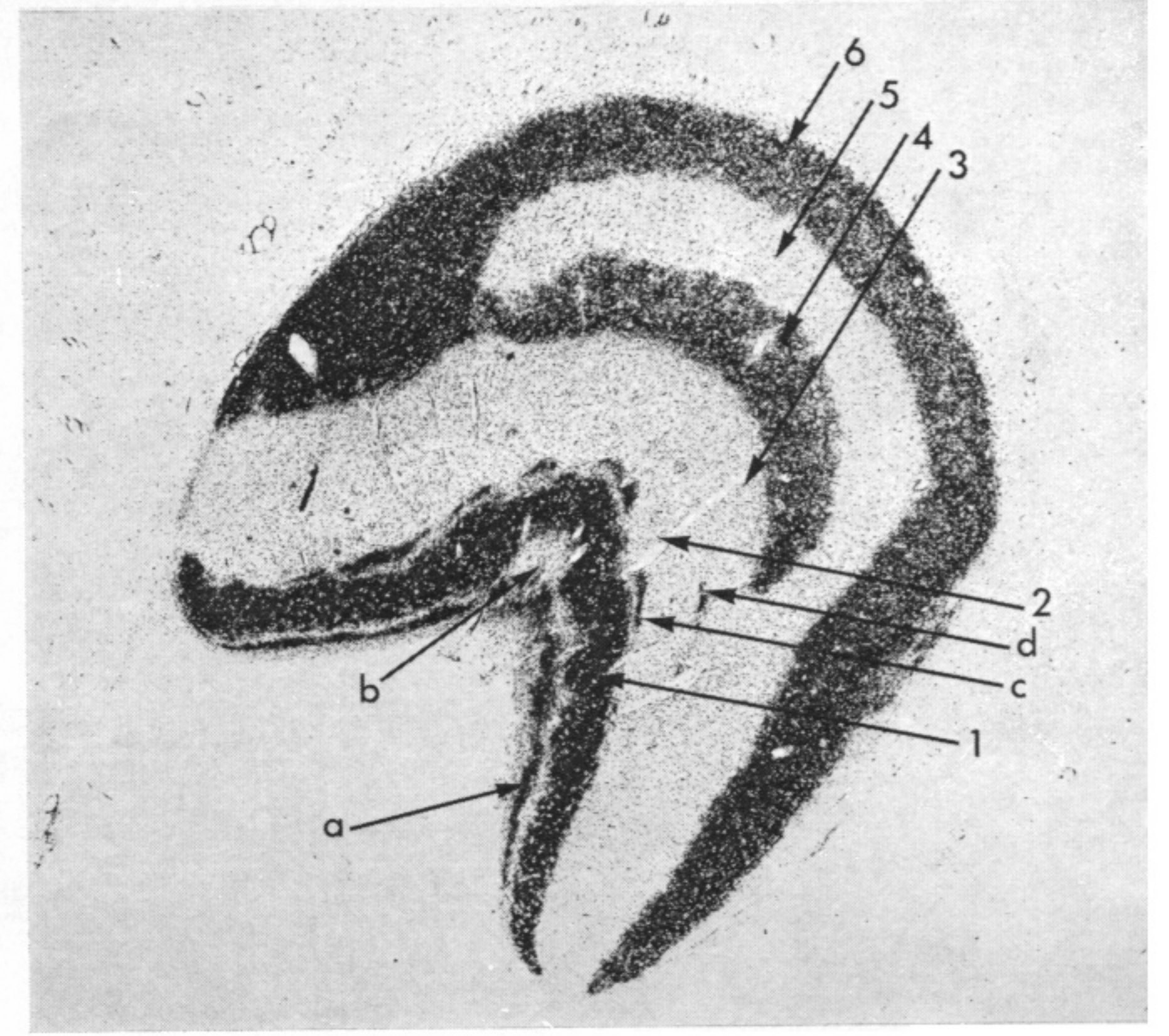
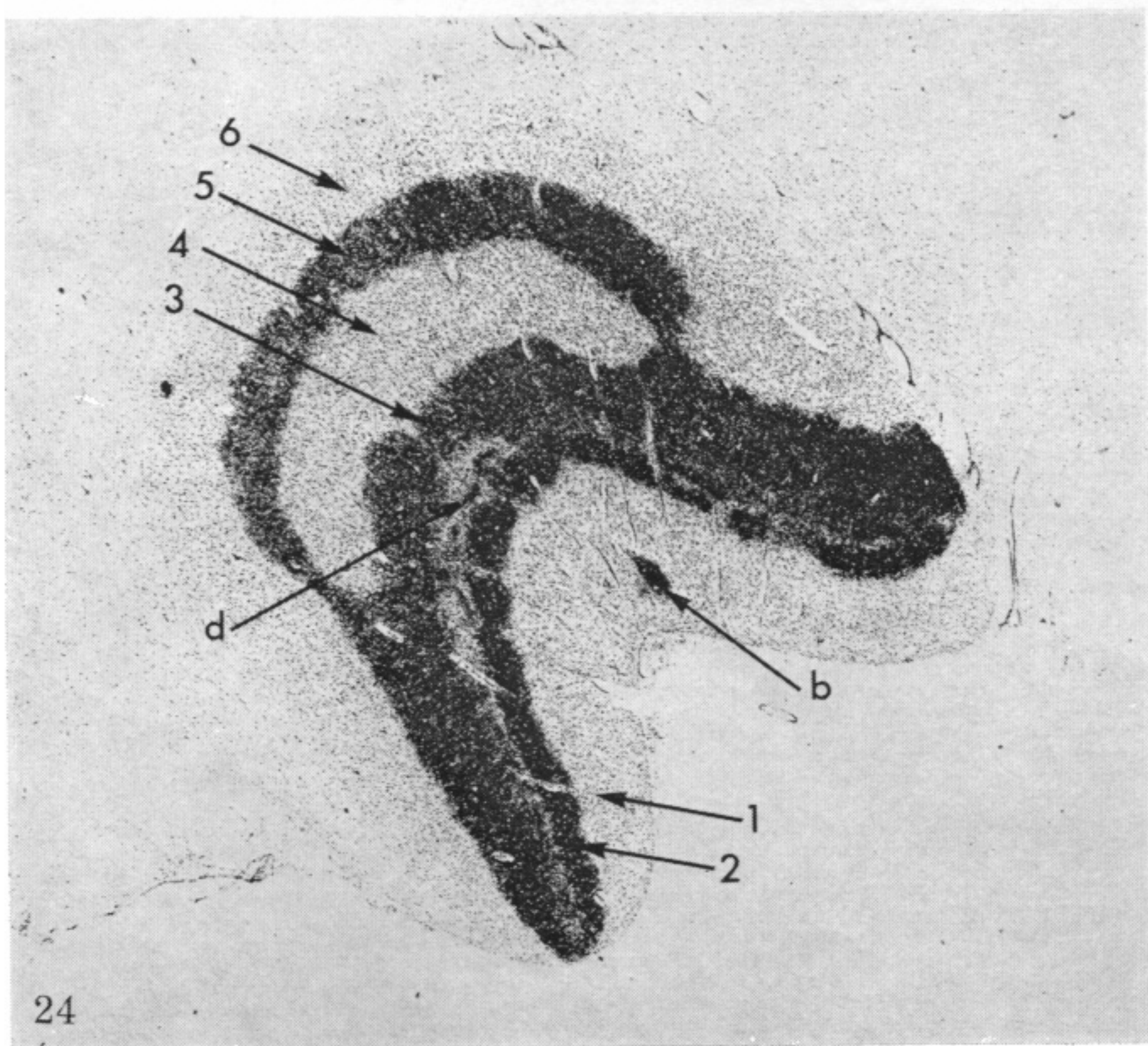
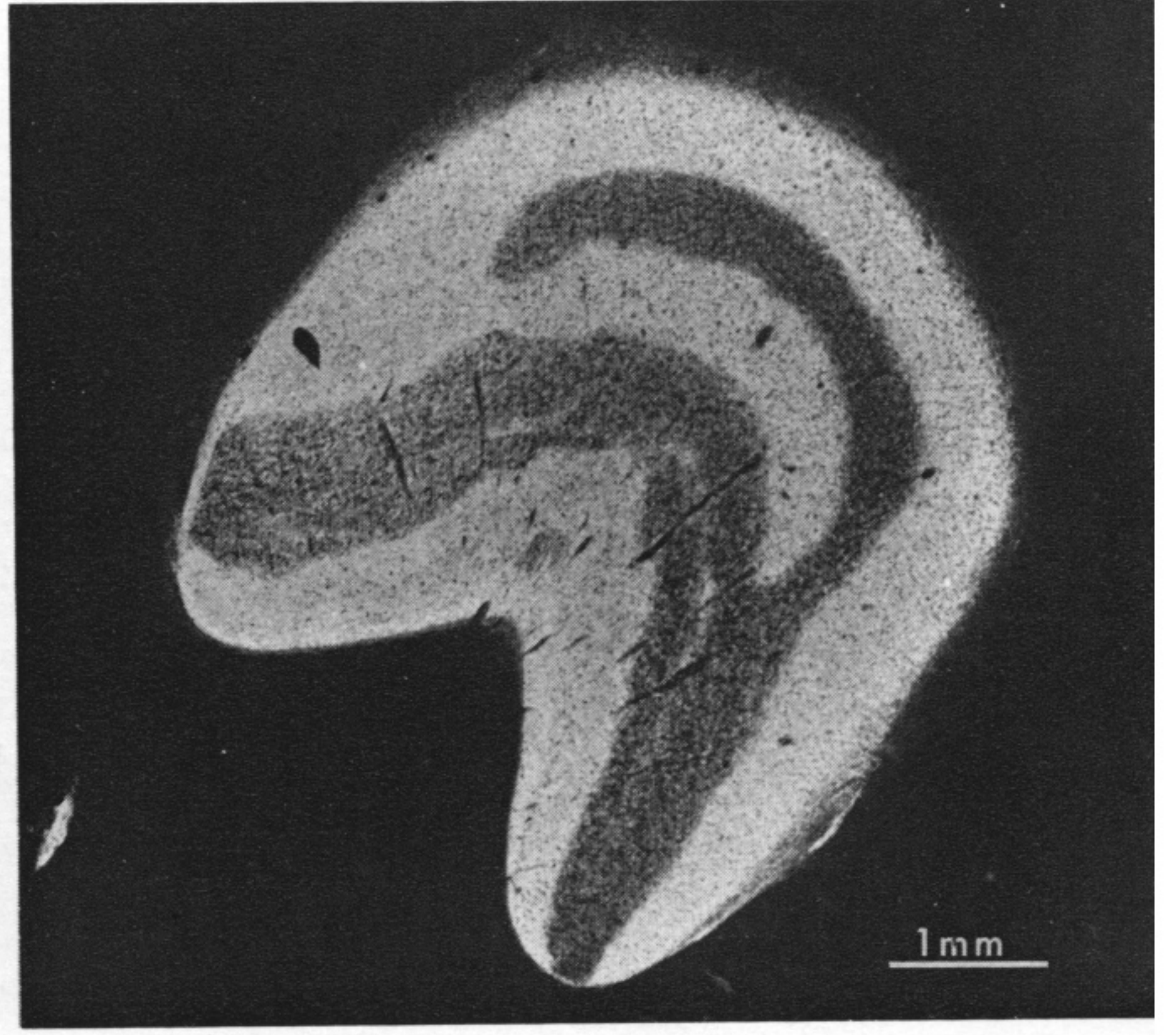
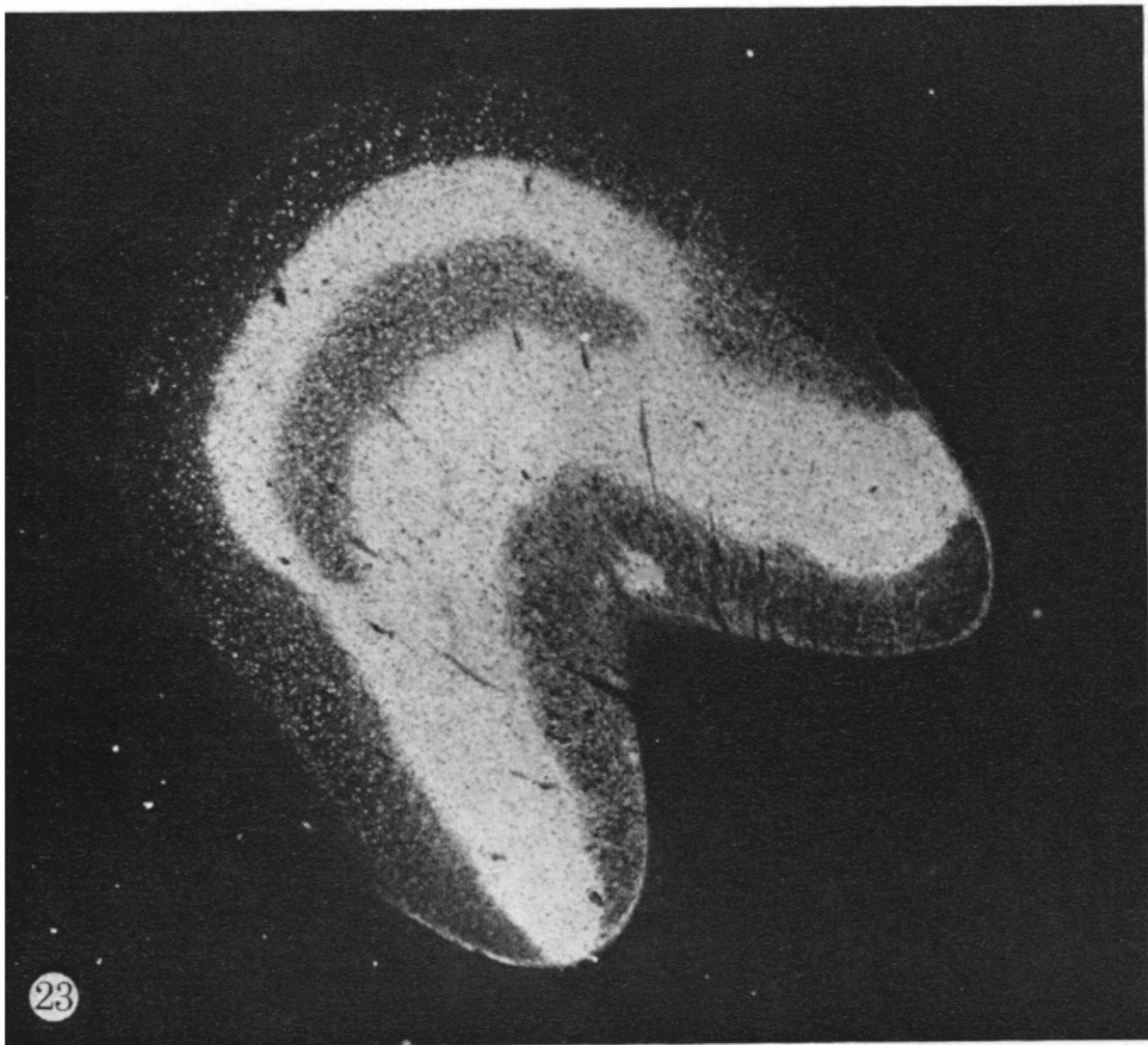

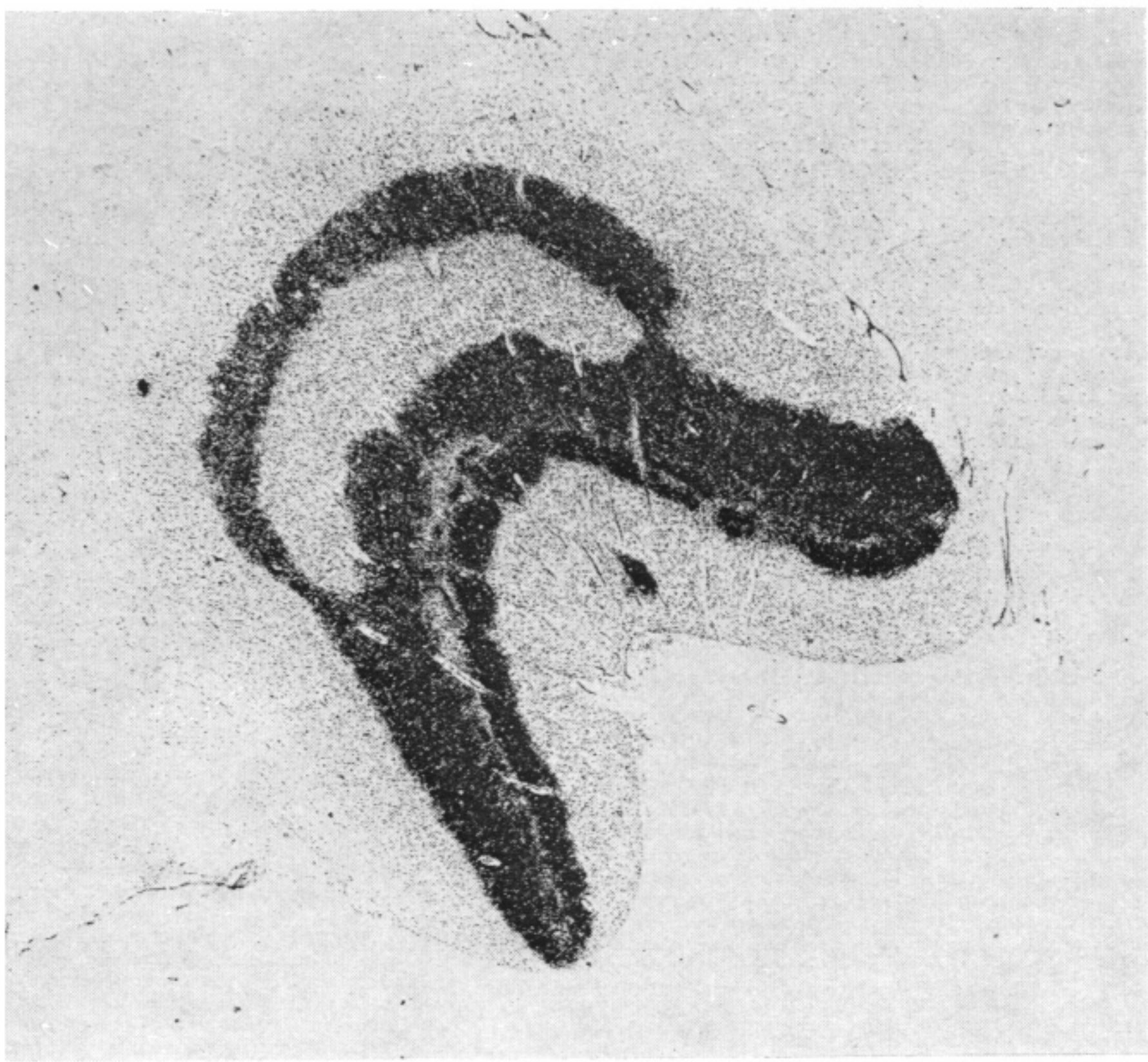
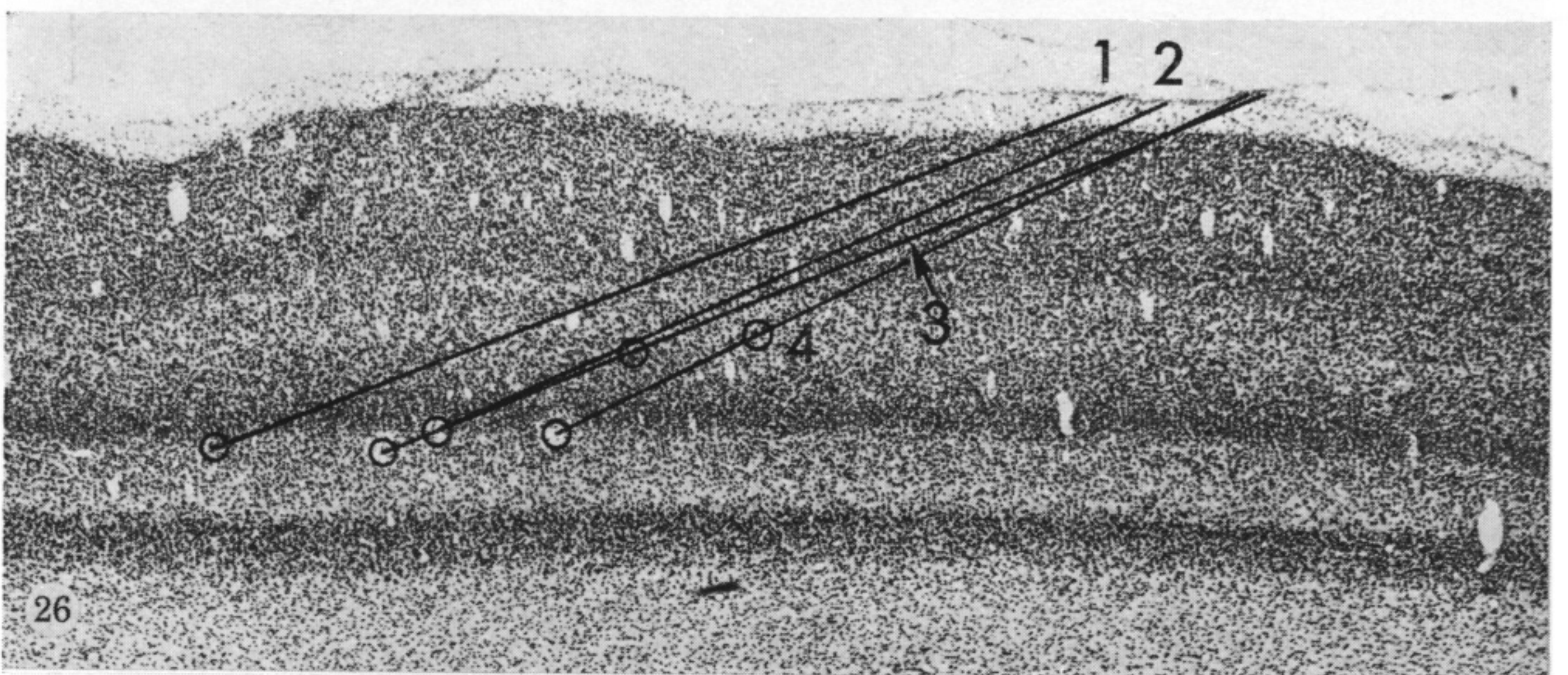
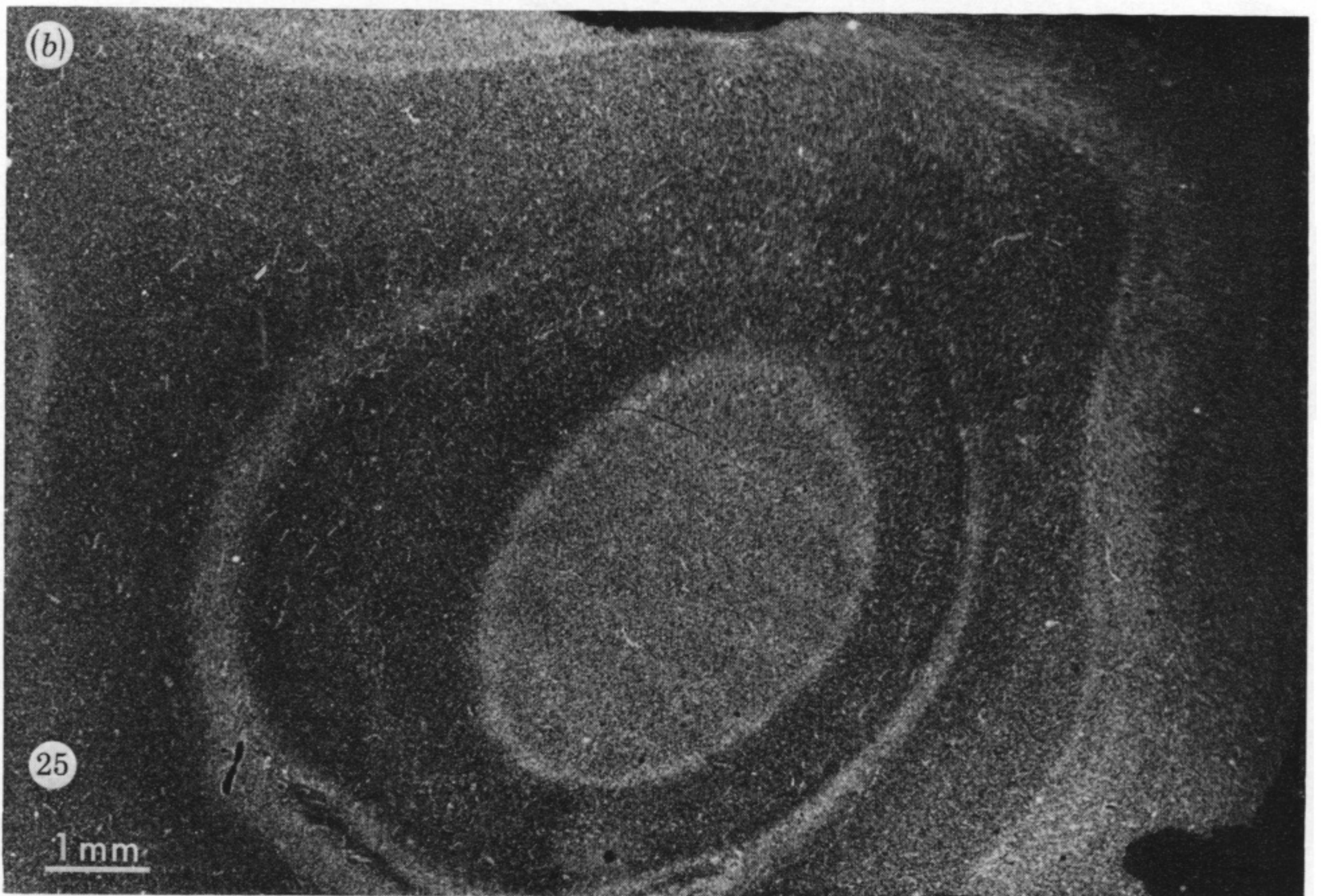
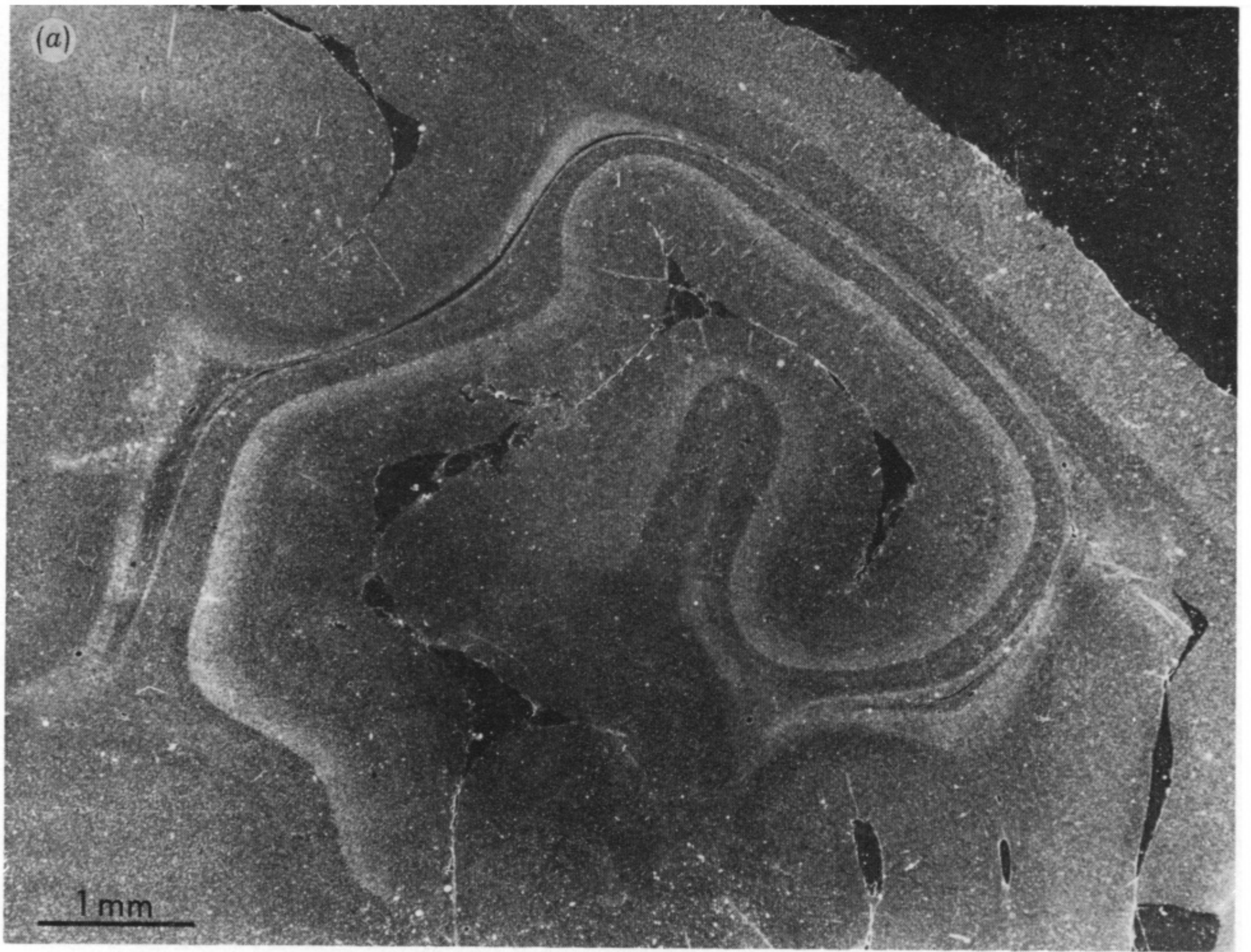
FIGURE 20. This is the counterpart of figures 13 and 15, for monkey no. 4; right eye closed at 3 weeks, until age 7 months; right eye injected. Dark-field autoradiographs of right occipital operculum. (*a*) tangential to layer IV C; (*b*) 120 μm deeper than *a*, tangential to layer V and intersecting it twice because of dimple in cortex. (*c*) reconstruction made up of 7 sections including *a* and *b*; total depth 640 μm . The labelled columns, corresponding to the closed eye, are markedly shrunken.



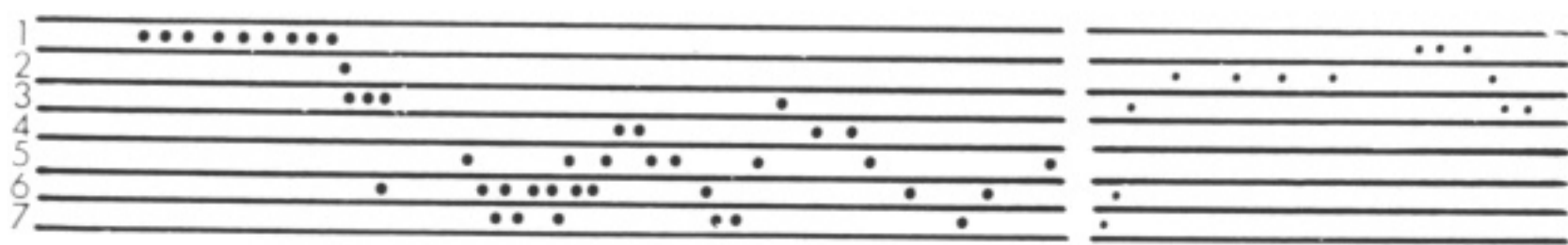
FIGURES 21 AND 22. For description see opposite.



FIGURES 23 AND 24. For description see opposite.



OD.
GROUP



LAYER IV_c

II, III, & IV_{a,b}

1 mm

FIGURES 25 AND 26. For description see opposite.